International Journal of Advanced Biochemistry Research

ISSN Print: 2617-4693
ISSN Online: 2617-4707
NAAS Rating (2026): 5.29
IJABR 2026; SP-10(6): 1155-1165
www.biochemjournal.com
Received: 04-05-2026
Accepted: 06-06-2026

Pragati Kumari
Jai Research Foundation, N.H. No. 48, Near Daman Ganga Bridge, Valvada, Valsad, Gujarat, India

Amit A Shiwal
Jai Research Foundation, N.H. No. 48, Near Daman Ganga Bridge, Valvada, Valsad, Gujarat, India

Dhvani Goti
Bhagwan Mahavir Center for Advanced Research, Bhagwan Mahavir University, Gujarat, India

Kunjan Shah
Jai Research Foundation, N.H. No. 48, Near Daman Ganga Bridge, Valvada, Valsad, Gujarat, India

Sudhakar Jadhav
Jai Research Foundation, N.H. No. 48, Near Daman Ganga Bridge, Valvada, Valsad, Gujarat, India

Manish Patel
Jai Research Foundation, N.H. No. 48, Near Daman Ganga Bridge, Valvada, Valsad, Gujarat, India

Corresponding Author:
Amit A Shiwal
Jai Research Foundation, N.H. No. 48, Near Daman Ganga Bridge, Valvada, Valsad, Gujarat, India

Comparative evaluation of antimicrobial and healing properties of *Argyreia nervosa* leaf extract in excision wound model

Pragati Kumari, Amit A Shiwal, Dhvani Goti, Kunjan Shah, Sudhakar Jadhav and Manish Patel

DOI: https://www.doi.org/10.33545/26174693.2026.v10.i6Sn.8788

Abstract
Argyreia nervosa, a well-known Indian medicinal plant traditionally used in Ayurveda, is recognized for its diverse pharmacological properties. This study investigates the antimicrobial and wound healing potential of *A. nervosa* leaf extract in an excision wound model in rats, aiming to determine which activity predominantly contributes to the healing process. The excision wound model was selected to evaluate wound healing activity and experimentally infected with the *S. aureus* (0.5 MacFarland standard/1.5 x 10^8 CFU/mL) within 2 h after excision. Rats were randomly divided into four groups (n = 6). The negative control group was kept untreated. A powdered extract of sun-dried *A. nervosa* leaves, prepared using the decoction method. Wounds were covered with powdered extract daily for 21 consecutive days. Parameters i.e. size of the wound area and microbial load, were determined. *A. Nervosa leaf* extract led to 2 to 3-fold reduction in *S. aureus* at the wound site within 3 days and 96% inhibition from day 1 microbial level by day 15 of application. Similarly, *A. Nervosa* leaf extract produced faster healing i.e., 30% by day 4 and up to 89% by day 16, while in vehicle control the percent contraction was only 14% on day 4 and 79% on day 16. This was further confirmed by lower levels of fibroplasia, hypertrophy/hyperplasia of squamous epithelium, and inflammatory cell infiltration during wound surface histology. So, according to previous and present data indicates *A. Nervosa* leaf extract have greater antimicrobial activity than healing properties, which led to faster healing activity.

Keywords: *Argyreia nervosa*, wound healing, antimicrobial, excision, fibroplasia, tissue regeneration, bacteriological load

1. Introduction

A wound is a disruption in anatomical structure and function, skin being a primary surface barrier for the protection of the body. They are disruptions to the body's innate mechanisms. These wounds trigger an inflammatory response, leading to tissue breakdown and the formation of debris, which in turn could cause contamination from the airborne pathogen. Platelet-fibrin complex could stop bleeding/exposure to the circulatory system. The growth of the pathogen in the wound could potentially impair the immune response. Any delay in the healing of these wounds they become highly susceptible to microbial colonisation leading to infections, particularly by air-borne pathogenic bacteria, which can rapidly invade and proliferate in the injured tissue [1, 2]. These wounds create a direct entry portal for bacteria and pose a significant risk for the onset of systemic infections. Infected wounds tend to exhibit delayed healing due to an imbalance in microbiota and several localised factors that lead to the disruption of the normal wound healing process, which in turn leads to the persistent inflammatory response and impaired cellular regeneration [3]. Sometimes, the presence of infection often leads to the formation of odorous pus (if the exudate contains pus), which may include a variety of toxins released by microbiota, further worsening the wound. This toxic environment contributes to the necrosis of surrounding healthy cells, thereby prolonging the healing timeline and increasing the risk of chronic wound formation [4].

Argyreia nervosa, commonly known as the railway creeper or morning glory, is a perennial, woody climber belonging to the Convolvulaceae family, native to India and Southeast Asia [5].

It is a pleiotropic plant; its roots, leaves, stems, seeds, and flowers, have been reported to exhibit a diverse spectrum of pharmacological activities. These include their hepatoprotective, aphrodisiac, anti-inflammatory, anticonvulsant, immunomodulatory, antioxidant, analgesic, antimicrobial, Antiviral, antiulcer, central nervous depressant and Antidiarrheal activities [6]. *A. Nervosa is* also known for its potential to manage metabolic disorders, such as hyperglycemia, and its ability to act as an antiulcer, and antidiarrhea [7] l. Due to its wide pharmacological profile, *A. Nervosa has* garnered significant attention in modern phytotherapy and drug development research.

Recently, *A. Nervosa a* medicinal plant has been reported to facilitate the process of wound healing using its leaf extract [8]. Considerable evidence has shown that Silver nanoparticles of the plant's leaf extract have anti-microbial properties [6], as well as show a maximum zone of inhibition for various types of microorganisms [9]. Leaves of *A. Nervosa*, mainly contain β-sitosterol, 1-tricontanol and quercetin, which implicates clinical effects such as anti-inflammatory as well as anti-bacterial [10]. Leaf extract of *A. Nervosa* when applied topically promotes the healing of wounds more significantly as compared to oral application, in both control rats and alloxan-induced diabetic rats, where healing is otherwise delayed [8]. 50% ethanolic extract of the seeds in the preliminary biological screening shows anti-bacterial activity against *Staphylococcus aureus* [11]. The alcoholic extract of the root also exhibited statistically significant anti-inflammatory activity against the granuloma technique in albino rats [12]. The leaves of *A. Nervosa* are traditionally used to promote purulent wound healing, potentially reducing drug resistance emergence [8]. Rich in flavonoids, saponins, tannins, and alkaloids, these phytochemicals exhibit antibacterial properties and contribute to various stages of wound healing, including inflammation, tissue regeneration, and collagen synthesis [13, 14].

It is important to note that, there are other ways in which plant materials can exert their antibacterial activity than directly inactivating the intended microorganism. The active compounds found in *A. Nervosa*, namely β-sitosterol, 1-tricontanol and quercetin can reduce the virulence of bacterial invaders or increase their susceptibility to antibiotic treatment by altering the metabolism of the bacterial cell, regulating gene expression, or interfering with various molecular targets within the bacterial cell. One such mechanism is by interfering with antimicrobial resistance mechanisms [6, 15]. The *A. Nervosa* plant contains various phytochemicals namely alkaloids, flavonoids, saponins, tannins, steroids, terpenoids, and phenolic acids (caffeic and chlorogenic acids) they have shown meaningful potential in the prevention and treatment of microbial infections and wounds. Phytochemicals with anti-microbial, antioxidant, and wound-healing properties promote blood coagulation, combat infections, and quicken the healing process [16].

It has been found that plants with high polyphenols and flavonoid content have exceptional wound-healing properties. As demonstrated by [16] water extracts of *A. Nervosa* leaves have a remarkable amount of total phenolic (110.8±0.19 mg GAE/g) and flavonoid contents (76.60±0.36 mg RE/g) when compared with the Gallic acid as standard. The main reasons phenolic aids in wound healing are because they are astringent, antibacterial, and scavenge free radicals. Due to their antibacterial and anti-oxidative qualities, polyphenolic components like flavonoids can aid in the excellent healing of wounds by blocking lipid peroxidation, which prevents cell damage and increases the vitality of collagen fibrils.

Thus, it can be intriguing whether *A. Nervosa* leaf extract and its phytochemical interaction with the wound's innate mechanism endogenously play an active role in inhibiting microbial growth and promoting wound healing. The present work aims to fill this gap by comparing the effectiveness of the leaf extract in inhibiting microbial growth and promoting wound healing in a controlled rat model. By assessing these activities, the study provides a clearer understanding of the plant's therapeutic potential and its possible applications in modern healthcare. This investigation into *A. Nervosa* aims to validate its traditional uses and explore its dual benefits in combating infections and enhancing wound healing, potentially offering new avenues for treatment in clinical settings.

2. Materials and methods

2.1 Collection and Identification of Plant Materials

Leaves of the *A. Nervosa* were collected from the regional area of Gadarpur, Uttarakhand and authenticated by Dr. M. N. Reddy, Head of the Bioscience Department, Veer Narmad South Gujarat University, Surat, Gujarat (voucher specimen number: BVBRC206).

2.2 Animals

Adult male rats of 238–285 g were obtained from the Animal Breeding Facility, Jai Research Foundation. They were housed in an environment-controlled room, in sterile solid floor polypropylene mouse cages (size: 290 × 220 × 140 mm), under the controlled conditions (22±3 °C and 12 h light/dark cycle, light on at 06:00 am) with free access to food and water. The experimentation was approved by the "Institutional Animal Ethics Committee (IAEC)" JRF. The experiment was undertaken in compliance with the guidelines of the "Association for Assessment and Accreditation of Laboratory Animal Care (AAALAC) International" and "Guidelines for Laboratory Animals Facility" issued by the Committee for the Control and Supervision of Experiments on Animals (CCSEA), India.

2.3 Preparation of extract

The freshly collected leaves were sun-dried and ground to make fine powder. The powder was extracted with water in a 1:8 ratio. The decoction was then boiled and concentrated until only one-eighth of the original volume remained. The extract was then cooled and strained, the filtrate was further air-dried and stored in airtight bottle (Fig. 1) [17].

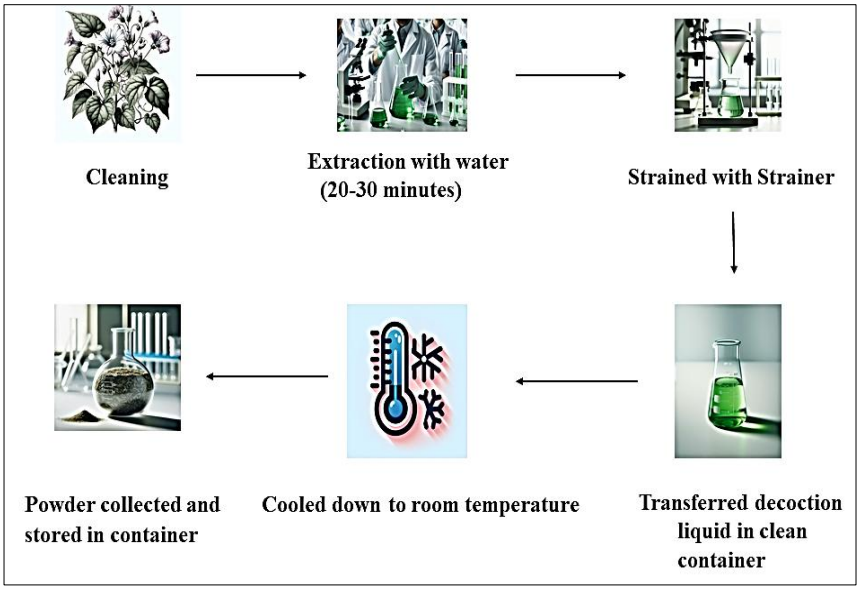

Fig 1: Nervaosa leaf Extract Preparation

2.4 Excision wound creation

All subjects were experimentally novices at the beginning of the study. Excision wounds were used to study the Wound Surface Area (mm), Percentage (%) of Wound Contraction, Bacteriological Load in Wound Surface (CFU/ml), and its Microscopic Examination. All wounds were of full-thickness type, extending up to the adipose tissue. Rats were anaesthetized with xylazine (10 mg/kg, i.p.) and ketamine (100 mg/kg, i.p.). The stage of an anaesthesia was decided on the base of the tail pinch, pedal, and pupillary reflexes. Surgical procedure was initiated after the complete absence of all the reflexes and an area of about ≈500 mm^2 was marked on the back of the rat by a standard ring.

The full thickness of the marked skin was then cut carefully. In addition, a new series of experiments for bacteriological load on the wound surface was carried out, pathogenic strains of *Staphylococcus aureus* were grown on nutrient agar medium at 37°C for 24 hours and then suspension was prepared comparing the turbidity with 0.5 Mac Farland. To induce infection, 0.1 mL of the above inoculum (1.5 x 10^8 CFU/mL) was inoculated on the wound area of each animal. The infection was allowed to be induced for 24 hr and the treatment using *A. Nervosa* leaf extract was topically applied thereafter [18, 19]. The application site was covered by a porous gauze dressing (not more than 8 ply) and non-irritating tape. On the next day approximately 24 hours after exposure, the dressing was removed from the rat using scissors. Also following excision, the rats were individually in the cage to avoid any disturbance. Their bedding material was changed daily to avoid microbial contamination. Animals were closely observed for any unwanted infection, and those that showed any sign of infection were separated, excluded from the study and replaced. No typical post-operative care was taken as no blood loss was observed in all animals. However, to reduce surgical pain in rats, rats were treated with Meloxicam (10 mg/kg b. wt.) after completion of surgery.

2.5 Experimental groups

For the accomplishment of the study, 18 infected male rats with *S. aureus* were randomly divided into three groups:

- **Group I: Negative control group:** the animals underwent surgery but did not receive any treatment but received sterile water for injection (SWFI) applied topically as a vehicle.
- **Group II: positive control group:** This animal underwent surgery and received standard treatment 2% w/w Mupirocin Ointment applied topically.
- **Group II: low dose:** The animals underwent surgery and were treated with *A. Nervosa* leaf extract at a dosage of 100 mg/kg body weight per day.
- **Group IV: high dose:** The animals underwent surgery and were treated with *A. Nervosa* leaf extract at a dosage of 1000 mg/kg body weight per day.

The selection of doses of *A. Nervosa* leaf extract was selected by considering the minimum inhibitory concentration (MIC) as per a previously published *in-vitro* study for microbial strain (*Staphylococcus aureus*) i.e., 100 mg/kg b. wt./day [20, 21]. The dose of positive control was selected as 10 mg/kg b. wt. /day based on a previously published *in-vivo* study [22]. *A. Nervosa* leaf extract at the dose of 100 and 1000 mg/kg bwt/day was applied topically [18] for a consecutive period of 21days [17, 19].

2.6 Wound surface area (mm) & percentage (%) of wound contraction: The means of wound surface area measurement and percentage of wound contraction between groups at different time intervals were measured by the Vernier calliper (Mitutoyo Corporation, Japan) on the day of excision and subsequently on an alternative day (Days 2, 4, 6, 8, 10, 12, 14, 16, 18, 20 and 22). The area of the wound on the day of wound excision was considered 100%. The rate of wound contraction is calculated as given in the formula below [23].

$$\text{Percentage (\%) of Wound Contraction} = \frac{\text{Initial day wound size- Specific day wound size}}{\text{Initial day wound size}} \text{X } 100$$

2.7 Anti-microbial rate

The severity of the bacterial infection was quantitatively assessed every alternate day (Days 1, 3, 5, 7, 9, 11, 13, 15, 17, 19, and 21) by collecting swab samples. Each swab was then rinsed in 1 mL of sterile nutrient broth, and colony-forming units per millilitre (CFU/mL) were determined using the spread plate method. Serial dilutions were performed up to a 10^{-6} dilution to reduce the microbial load. Three selected dilutions, spaced alternately, were plated onto the surface of sterile nutrient agar plates. All plates were incubated in a bacteriological incubator at 37°C for approximately 24 hours. After incubation, the CFU/mL was calculated [24].

2.8 Histopathological examination

The rats were euthanized on day 22 followed by hematoxylin and eosin (H&E) staining is most commonly used for histopathological examinations. Hence, its integrity in the quality of staining has paramount importance [25]. The materials required for the procedure included reagents such as Eosin Y solution, ethanol (100%, 95%, and 70%), Mayer's hematoxylin solution, and Permount mounting medium. The tissue samples were properly embedded in paraffin, sectioned, and mounted onto glass slides. The staining process involved several key steps. First, paraffin was removed from the slides by soaking them in xylene.

The slides were then hydrated by sequential immersion in ethanol solutions of decreasing concentrations (100%, 95%, and 70%) and subsequently rinsed with tap water. Following this, the tissue sections were stained with hematoxylin and rinsed with water. Eosin Y was then applied to stain the tissues, after which the samples were dehydrated through graded ethanol and cleared with xylene. Finally, a drop of Permount was placed on each tissue section, and a coverslip was applied [26]. The stained tissues were examined under a light microscope (1000× magnification) and graded subjectively as mild (+), moderate (++), or severe (+++) for various parameters including epidermal fibroplasia, hypertrophy/hyperplasia, squamous epithelium, inflammatory infiltrates, and the presence of wounds or ulcers, in order to evaluate epidermal and dermal remodelling.

2.9 Statistical analysis

Data were analysed with Graph Pad Prism Version 10.4.1 (627), November 18, 2024, for Windows- 64 bit (Graph Pad Software Inc., San Diego, CA, United States) statistical package program. The results are presented as means±S.E.M. The effects of *A. Nervosa* leaf extracts treatment at the dose of 100 mg/kg (G3) and 1000 mg/kg (G4) and 2% w/w Mupirocin ointment at the dose of 10 mg/kg (G2), the data obtained from these treatment groups were compared with a control group of dose 0 mg/kg (G1) and were statistically analysed by two-way analysis of variance (ANOVA) followed by post hoc Dunnett's test. A value of $p<0.05$ was considered significant.

3. Results

3.1 *A. Nervosa* leaf extract exhibits a faster reduction in wound surface area over time, indicating a natural wound-healing process

As shown in Fig. 2 and Table 1, *A. Nervosa* leaf extract on days 6 [F (3,20) = 1.933, $p<0.05$], 8 [F (3,20) = 1.224, $p<0.01$], 10 [F (3,20) = 0.8589, $p<0.01$], 12 [F (3,20) = 1.013, $p<0.001$], 14 [F (3,20) = 0.3487, $p<0.05$] 16 [F (3,20) = 0.8062, $p<0.001$], 18 [F (3,20) = 0.6818, $p<0.05$], and 22 [F (3,20) = 0.1895, $p<0.05$] at the dose of 100 mg/kg (G3) and 1000 mg/kg (G4) showed a significant effect on reducing the mean wound surface area (mm) and as compared to the control (G1) group. Post hoc Dunnett's multiple comparisons test analysis showed a significant reduction on day 6 [at 100 mg/kg ($p<0.05$)], day 8 [at 100 mg/kg ($p<0.05$)], day 10 [at 100 mg/kg ($p<0.05$) and at 1000 mg/kg ($p<0.01$)], day 12 [at 100 mg/kg ($p<0.001$) and at 1000 mg/kg ($p<0.05$)], day 16 [at 100 mg/kg ($p<0.001$) and at 1000 mg/kg ($p<0.01$)], day 18 [at 100 mg/kg ($p<0.05$)]. Conversely, the positive control (G2) group of 2% w/w Mupirocin ointment did not show statistically significant data [at 10 mg/kg ($p>0.05$) but, a noticeable improvement in wound surface area reduction, particularly during the early stages (days 2-10) can be seen. However, the rate of healing differed significantly on some days but the *A. Nervosa* leaf extract accelerates healing and highlights the potential effectiveness in enhancing wound repair.

Table 1: Wound Surface Area (mm) - Group Mean Values

Day	Wound Surface Area (mm)							
	G1 (N=6)		G2 (N=6)		G3 (N=6)		G4 (N=6)	
	Mean	SD	Mean	SD	Mean	SD	Mean	SD
PT	856.83	152.61	881.67	60.444	879.67	37.671	908.83	84.580
2	952.50	158.23	949.50	62.051	858.33	89.415	958.17	187.53
4	746.17	234.38	780.83	81.190	615.50	48.911	663.00	91.128
6	634.83	197.51	642.17	58.259	458.17	21.656	558.50	108.00
8	420.83	110.85	457.33	71.346	301.50	43.574	317.67	54.106
10	339.67	73.416	342.33	84.744	195.83	41.562	222.50	80.897
12	273.67	52.102	221.33	36.925	122.33	33.375	184.67	89.424
14	176.33	49.403	190.67	50.007	129.17	30.083	129.67	32.365
16	213.50	53.557	182.00	29.175	96.833	33.415	138.00	33.728
18	150.50	56.550	158.67	49.241	79.500	52271	140.83	22.085
20	80.67	40.75	105.2	56.40	60.50	50.79	117.7	35.44
22	57.67	37.01	50.83	21.49	27.17	24.29	85.33	20.79

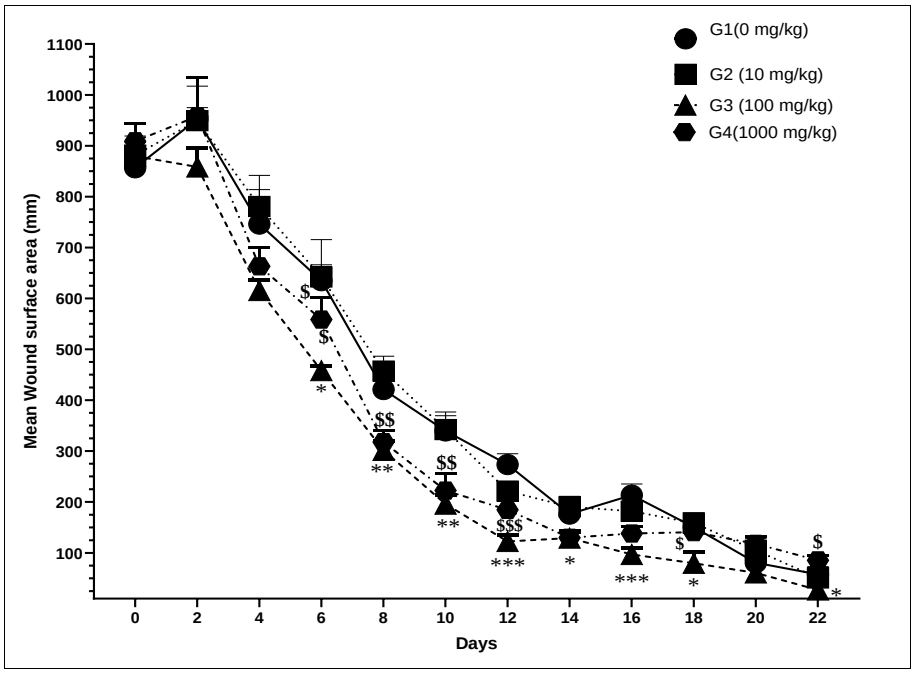

Fig 2: Wound Surface Area (mm)

Fig. 2 and Table 1. Effect of *A. Nervosa* leaf extract (100 mg/kg and 1000mg/kg) and 2% w/w Mupirocin ointment (10 mg/kg) on the means of wound surface area (mm). An excision wound was created in rats in addition with *S. aureus* infection (0.5 MacFarland standard/1.5 x 10^8 CFU/mL) induced for 24 hours. Thereafter, leaf extract of *A. Nervosa* was applied topically at the dose of 100 mg/kg and 1000 mg/kg and 2% w/w Mupirocin ointment was applied as a positive control at 10 mg/kg and means of wound surface area (mm) was measured using Vernier Calliper on the day of excision and subsequently on the alternate days. Each data represents means±SEM, n = 6. *** And $$$ $p<0.001$; ** and $$ $p<0.01$; * and $ $p<0.05$ compared to the control group (Two-way ANOVA followed by Dunnet's post hoc test).

3.2 *A. Nervosa* leaf extract enhanced wound contraction (%) - a key indicator of the healing process

As depicted in Fig. 3 and Table 2, *A. Nervosa* exhibits an intuitive visual comparison at various dosages of 100 mg/kg, and 1000 mg/kg on multiple days throughout the period. On day 2, 10 mg/kg, and 1000 mg/kg groups show negative wound contraction values [F (3,20) = 0.3669, $p>0.05$], while the 100 mg/kg group shows a positive mean value this could be attributed to an inflammatory phase of wound healing. A significant wound contraction (%) i.e. percent wound closure can be observed on day 4 [F (3, 20) = 4.277, $p<0.01$], on day 6 [F (3, 20) = 4.674, $p<0.01$], day 8 [F (3, 20) = 0.7246, $p<0.001$], day 10 [F (3, 20) = 1.154, $p<0.001$], day 12 [F (3, 20) = 0.6985, $p<0.001$], day 14 [F (3, 20) = 1.617, $p<0.05$], day 16 [F (3, 20) = 1.489, $p<0.001$], day 18 [F (3, 20) = 1.790, $p<0.05$], day 22 [F (3, 20) = 0.1370, $p<0.01$] at the dose of 100 mg/kg (G3) and 1000 mg/kg (G4) showed a significantly high percentage of wound contraction and as compared to the control (G1) group. Post hoc Dunnett's multiple comparisons test analysis showed a significant percentage of wound contraction on day 4 [at 100 mg/kg ($p<0.05$)], day 6 [at 100 mg/kg ($p<0.05$)], day 8 [at 100 mg/kg and 1000 mg/kg ($p<0.05$)], day 10 [at 100 mg/kg and 1000 mg/kg ($p<0.01$)], day 12 [at 100 mg/kg ($p<0.001$) and 1000 mg/kg ($p<0.01$)], day 16 [at 100 mg/kg ($p<0.001$) and 1000 mg/kg ($p<0.01$)], day 18 [at 100 mg/kg ($p<0.05$)]. However, the positive control (G2) group of 2% w/w Mupirocin ointment did not show statistically significant data [10 mg/kg ($p>0.05$)], but showed modest wound contraction starting from day 4, with a steady improvement throughout the period. So, we can say that all groups exhibit a plateau effect toward day 22, suggesting that the rate of wound contraction decreases as the wound approaches full closure. Based on the results, *A. Nervosa* enhances the early stages of healing, ultimately leading to faster wound closure.

Table 2: Percentage (%) Wound Contraction - Group Mean Values

Day	Percentage (%) Wound Contraction							
	G1 (N=6)		G2 (N=6)		G3 (N=6)		G4 (N=6)	
	Mean	SD	Mean	SD	Mean	SD	Mean	SD
2	-11.72	11.19	-8.232	11.46	2.210	11.54	-5.332	16.31
4	14.07	14.64	11.21	9.802	30.04	4.535	26.97	7.560
6	26.87	11.78	26.69	10.19	47.86	2.794	38.79	9.147
8	51.05	7.991	47.76	9.959	65.68	5.108	64.64	7.406
10	60.42	4.025	60.85	11.02	77.65	5.132	75.68	8.050
12	67.69	6.209	74.77	4.492	86.08	3.828	79.76	9.351
14	79.35	4.605	78.26	6.022	85.35	3.248	85.71	3.399
16	74.69	7.095	79.35	3.015	89.07	3.451	84.73	3.724
18	82.75	4.034	81.95	5.701	91.02	5.705	84.51	1.991
20	90.76	3.479	88.08	6.174	93.18	5.561	86.98	3.952
22	93.48	3.052	94.14	2.827	96.95	2.654	90.60	2.133

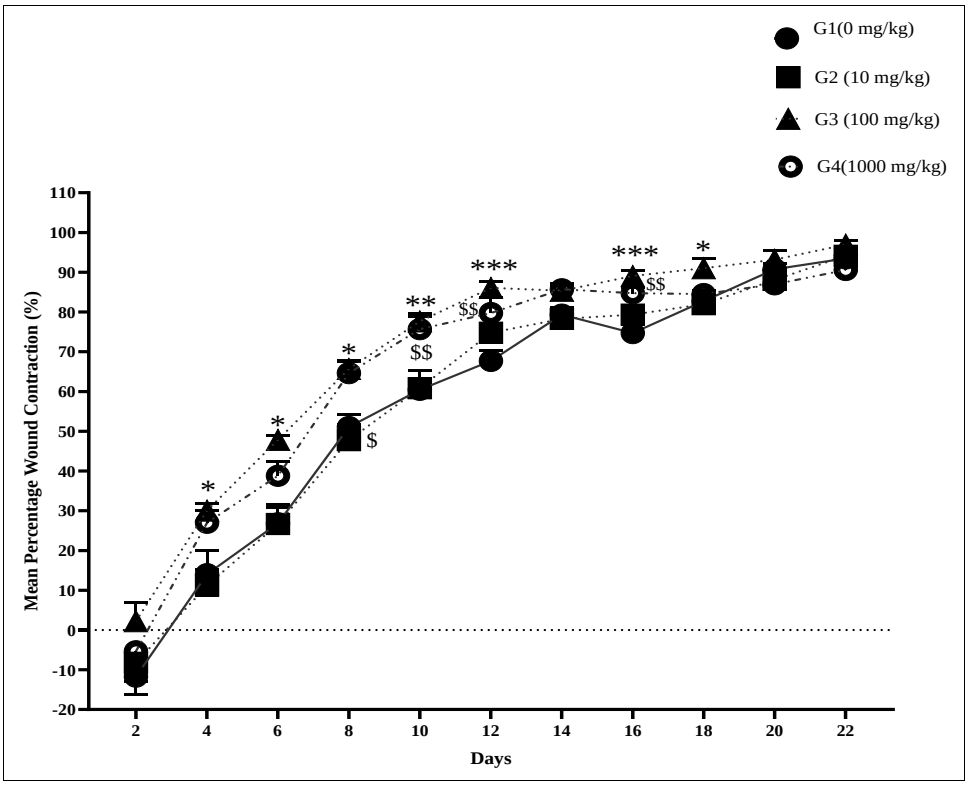

Fig 3: Mean Percentage Wound Contraction (%)

Fig. 3 and Table 2. Effect of *A. Nervosa* leaf extract (100 mg/kg and 1000mg/kg) and 2% w/w Mupirocin ointment (10 mg/kg) on the means of percent wound contraction. An excision wound was created in rats in addition with *S. aureus* infection (0.5 MacFarland standard/1.5 x 10^8 CFU/mL) induced for 24 hours. Thereafter, leaf extract of *A. Nervosa* was applied topically at the dose of 100 mg/kg and 1000 mg/kg and 2% w/w Mupirocin ointment was applied as a positive control at 10 mg/kg and means of percent wound contraction was measured using Vernier Calliper on the day of excision and subsequently on the alternate days. Each data represents means±SEM, n = 6. ***p<0.001; ** and $$ p<0.01; * and $ p<0.05 compared to the control group (Two-way ANOVA followed by Dunnet's post hoc test).

3.3 *A. Nervosa* leaf extract illustrates a dose-dependent reduction in bacterial load – possessing anti-microbial properties

Fig. 4 and Table 3, show that *A. Nervosa* leaf extract demonstrates the efficacy of varying doses of 100 mg/kg, and 1000 mg/kg in reducing the bacteriological load on wound. On day 1 [F (3,20) = 0.7795, p>0.05], all the experimental groups demonstrated a similar high initial bacterial load, approximating 20 million CFU/mL, indicative of a consistent baseline level of bacterial contamination across all the groups. A significant reduction in bacteriological load was observed on day 3 [F (3, 20) = 1.660, p<0.001], day 5 [F (3, 20) = 1.973, p<0.001], day 7 [F (3, 20) = 0.2638, p<0.001], day 9 [F (3, 20) = 0.2381, p<0.001], day 11 [F (3, 20) = 0.4825, p<0.001], day 13 [F (3, 20) = 1.780, p<0.001], day 15 [F (3, 20) = 2.483, p<0.001], day 17 [F (3, 20) = 3.405, p<0.01], day 19 [F (3, 20) = 4.417, p<0.01], day 21 [F (3, 20) = 3.049, p<0.001] at the dose of 10 mg/kg (G2), 100 mg/kg (G3) and 1000 mg/kg (G4) showed a significant, dose-dependent reduction in bacterial load as compared to the control (G1) group. Pos hoc Dunnett's multiple comparisons test analysis revealed a significantly high reduction in bacterial load on day 3 [at 10 mg/kg, 100 mg/kg and 1000 mg/kg (p<0.001)], day 5 [at 10 mg/kg, 100 mg/kg and 1000 mg/kg (p<0.001)], day 7 [at 10 mg/kg, 100 mg/kg and 1000 mg/kg (p<0.001)], day 9 [at 10 mg/kg, 100 mg/kg (p<0.001), and 1000 mg/kg (p<0.01)], day 11 [at 10 mg/kg, 100 mg/kg and 1000 mg/kg (p<0.001)], day 13 [at 10 mg/kg, 100 mg/kg and 1000 mg/kg (p<0.001)], day 15 [at 10 mg/kg, 100 mg/kg and 1000 mg/kg (p<0.001)], day 17 [at 10 mg/kg (p<0.01), and 100 mg/kg (p<0.05)], day 19 [at 10 mg/kg,100 mg/kg (p<0.01), and 1000 mg/kg (p<0.05)], day 21 [at 10 mg/kg, 100 mg/kg and 1000 mg/kg (p<0.001)]. However, on day 17, significant results were not found in the G4 group [1000 mg/kg (p>0.05)]. Therefore, as depicted, this rapid and substantial decrease in bacterial contamination underscores the dose-response relationship and suggests that *A. Nervosa* leaf extract possesses antimicrobial properties that either directly inhibit bacterial growth or indirectly facilitate wound healing by reducing bacterial contamination and preventing secondary infections.

Table 3: Bacteriological load in wound surface (cfu/ml)

Day	Bacteriological Load in Wound Surface (CFU/mL)							
	G1 (N=6)		G2 (N=6)		G3 (N=6)		G4 (N=6)	
	Mean	SD	Mean	SD	Mean	SD	Mean	SD
1	6.21E+08	3.19E+08	7.22E+08	4.44E+08	4.28E+08	2.97E+08	5.70E+08	4.47E+08
3	7.87E+08	3.45E+08	1.45E+08	4.05E+07	1.73E+08	4.78E+07	2.07E+08	7.42E+07
5	7.74E+08	3.66E+08	3.51E+07	5.12E+07	1.17E+08	3.84E+07	1.46E+08	3.17E+07
7	2.51E+08	2.58E+07	2.78E+07	3.37E+07	9.01E+07	3.50E+07	1.06E+08	2.80E+07
9	1.21E+08	2.13E+07	1.31E+07	1.60E+07	5.27E+07	1.95E+07	6.99E+07	1.88E+07
11	9.19E+07	1.47E+07	8.51E+06	1.26E+07	2.55E+07	9.30E+06	3.63E+07	6.73E+06
13	7.59E+07	1.02E+07	4.53E+05	1.80E+06	1.59E+07	8.51E+06	2.27E+07	6.66E+06
15	5.55E+07	1.44E+07	3.96E+04	1.41E+04	8.50E+06	4.68E+06	1.19E+07	5.96E+06
17	2.84E+07	8.50E+06	3.33E+02	0.00E+00	6.11E+03	1.40E+04	1.15E+06	2.75E+06
19	2.84E+07	8.50E+06	3.33E+02	0.00E+00	3.33E+02	0.00E+00	4.44E+02	1.72E+02
21	1.53E+07	4.68E+06	3.33E+02	0.00E+00	3.33E+02	0.00E+00	3.33E+02	0.00E+00

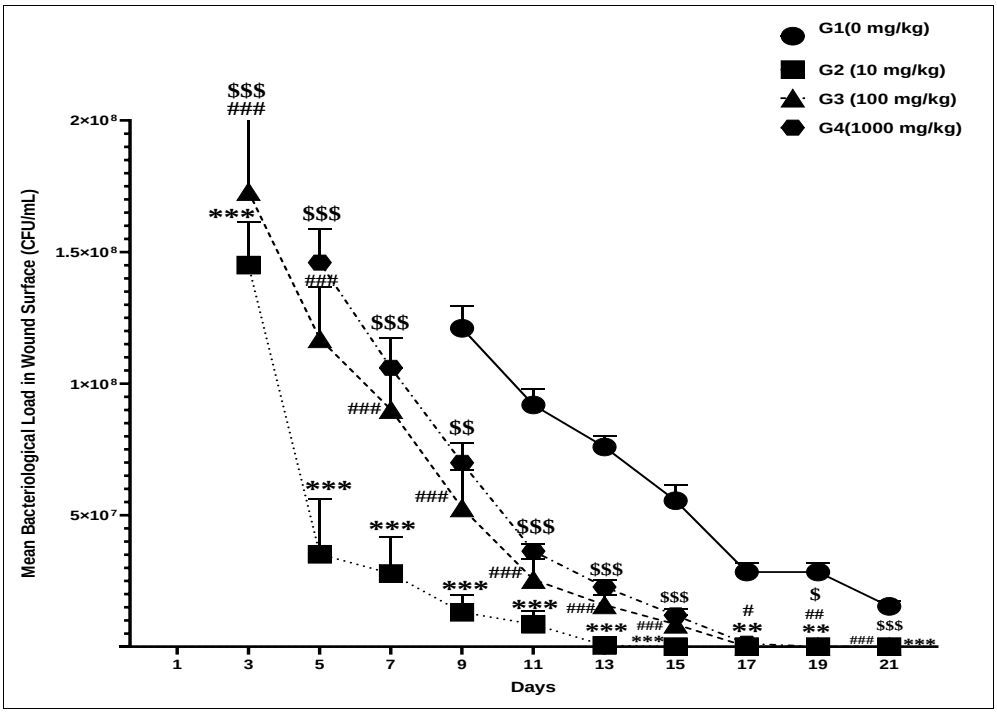

Fig 4: Mean Bacteriological Load in Wound Surface (CFU/mL)

Fig. 4 and Table 3. Effect of *A. Nervosa* leaf extract (100 mg/kg and 1000mg/kg) and 2% w/w Mupirocin ointment (10 mg/kg) on the means of Bacteriological Load on Wound Surface (CFU/mL). An excision wound was created in rats in addition with *S. aureus* infection (0.5 McFarland standard/1.5 x 10^8 CFU/mL) induced for 24 hours. Thereafter, leaf extract of *A. Nervosa* was applied topically at the dose of 100 mg/kg and 1000 mg/kg and 2% w/w Mupirocin ointment was applied as a positive control at 10 mg/kg and the severity of bacterial infection was quantitatively assessed by collecting swab samples from the wound, serially diluted, placed on agar plates and incubated for 24 hr and means of bacteriological load on the wound surface and assessed subsequently on the alternate days. Each data represents means±SEM, n = 6. ***, $$$, ### $p<0.001$; **, $$, and ## $p<0.01$; *, $, and # $p<0.05$ compared to the control group (Two-way ANOVA followed by Dunnet's post hoc test).

3.4 *A. Nervosa* leaf extract ameliorates tissue regeneration and the healing process

As depicted in Fig. 5 and Table 4. Specimens of wound tissue were collected on day 21 for histopathology examination. The histopathological assessment mainly in the dose of 100 mg/kg (G3) and 1000 mg/kg (G4) groups revealed marked re-epithelization/hyperplasia of the squamous epithelium, hair follicles, collagen deposition, neovascularization, and fibrous tissue proliferation (Fig. 5 - C, D). And, all the groups showed distinct patterns in fibroplasia, epithelial changes, inflammatory cell infiltration, and wound severity (Fig. 5 - A, B, C, D).

Histological sections of wound surface tissue taken from the Control group of dose 0 mg/kg (G1) exhibited marked (n=1), mild (n=2), minimal (n=2) and, moderate fibroplasia (n=1). Furthermore, G1 showed mild (n=4) and, minimal hypertrophy/hyperplasia of squamous epithelium (n=2) and, minimal inflammatory cell infiltrate (n=4), marked (n=1) and, severe wound/ulcer presence (n=3). The overall findings suggest impaired and suboptimal wound healing in the control group. Animals from the Positive control group 10 mg/kg (G2) displayed moderate (n=4), with mild fibroplasia (n=2). Hypertrophy/ Hyperplasia of squamous epithelium was predominantly noted mild (n=4) with few minimal cases (n=2). Inflammatory cell infiltrate was marked (n=3), and mild (n=2), with marked (n=2), moderate (n=1) and, severe wound/ulcer presence (n=2). These

observations indicate partial improvement in wound healing with persistent inflammation and epithelial changes. The 100 mg/kg (G3) showed balanced fibroplasia with cases of mild, moderate, and minimal (n=2 each). The prominent characteristics of were the minimal Hypertrophy/ Hyperplasia of squamous epithelium (n=4) and, mild (n=4), as well as the presence of moderate (n=1), minimal (n=4), and mild (n=1) inflammatory cell infiltrate, with balanced wound or ulcer presence with cases of marked, mild, moderate and, severe (n=1 each). The findings suggest a more regulated healing response with controlled tissue regeneration and inflammation. The 1000 mg/kg group (G4) was predominated by mild (n=5) and moderate fibroplasia (n=1) while minimal hypertrophy (n=4), marked (n=4), and mild hypertrophy/ hyperplasia of squamous epithelium (n=2), mild (n=4) to minimal (n=2) inflammatory cell infiltrate and, marked to moderate presence of wound/ulcer (n=2 each) were observed. So, the changes exhibited in G4 shows significant healing efficacy, characterized by efficient fibroplasia, controlled epithelial changes, minimal inflammatory response, and reduced ulcer severity.

In conclusion, the 100 mg/kg (G3) and 1000 mg/kg (G4) treatment groups demonstrated significant advancements in wound healing, characterized by improved tissue regeneration, controlled inflammation, and reduced wound severity. In contrast, the control (G1) and positive control (G2) groups exhibited suboptimal healing with persistent inflammatory responses. Specifically, G1 showed higher fibroplasia and severe inflammatory infiltration, while G4 exhibited more pronounced mild fibroplasia, marked hyperplasia, and moderate squamous epithelial changes. The variability in inflammatory infiltrates and wound severity across the groups highlights the heterogeneity of tissue responses in wound healing and chronic ulcer pathology. These findings align with established descriptions of chronic wound histopathology, where persistent inflammation, fibroplasia, and epithelial changes are central features.

Table 4: Histopathological scoring of tissue changes across experimental groups

Group	Fibroplasia				Hypertrophy/Hyperplasia of squamous epithelium		Infiltrate inflammatory cells			Wound/Ulcer			
	Marked	Mild	Minimal	Moderate	Mild	Minimal	Mild	Minimal	Moderate	Marked	Mild	Moderate	Severe
G1	1	2	2	1	4	2	0	4	0	1	0	0	3
G2	0	2	0	4	4	2	3	2	0	2	0	1	2
G3	0	2	2	2	2	4	1	4	1	1	1	1	1
G4	0	5	0	1	2	4	4	2	0	2	2	2	0

Table 4: Histopathological analysis of tissue responses across four experimental groups. The table presents the incidence of fibroplasia (marked, mild, minimal, and moderate), hypertrophy/hyperplasia of squamous epithelium (mild, and minimal), inflammatory cell infiltrate (mild, Minimal, and moderate), and wound/ulcer presence (marked, mild, moderate, and severe) in Groups G1- G4. Values represent the number of samples exhibiting each condition within each group (n=6 per group).

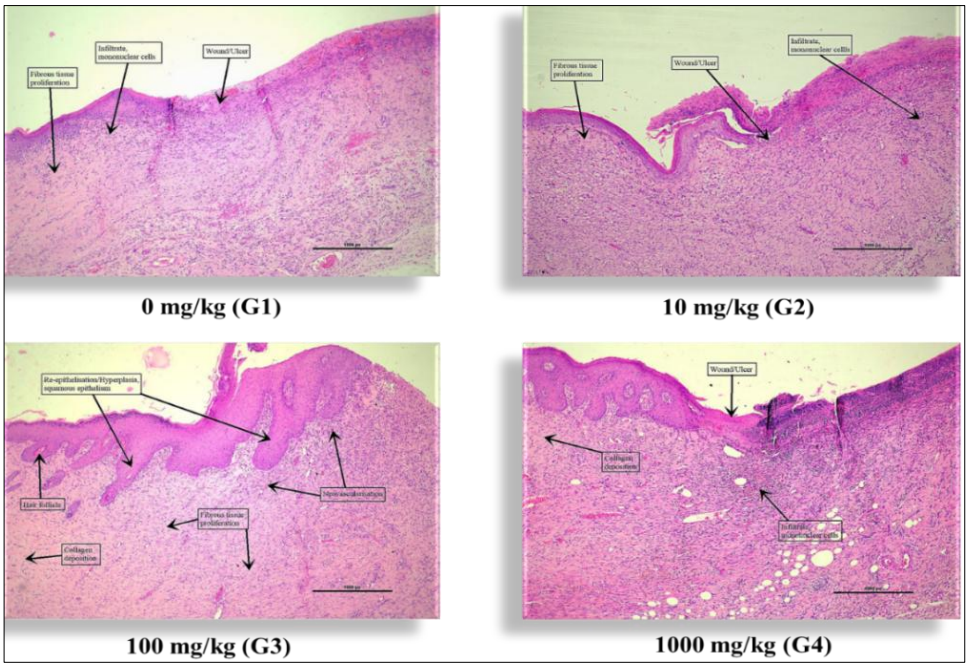

Fig 5: Hstological stsges of wound heading

Fig. 5. Effect of *A. Nervosa* leaf extract (100 mg/kg and 1000mg/kg) and 2% w/w Mupirocin ointment (10 mg/kg) induced Histopathological alteration (1000 px) on the specimens of wound tissue, stained with H&E. Which was created in rats in addition with *S. aureus* infection (0.5 MacFarland standard/1.5 x 10^8 CFU/mL) induced for 24 hours. The 100 mg/kg (G3) and 1000 mg/kg (G4) groups revealed marked re-epithelization/hyperplasia of the squamous epithelium, hair follicles, collagen deposition, neovascularization, and fibrous tissue proliferation.

4. Discussion

The present study investigated the Antimicrobial and Healing properties of *A. Nervosa* Leaf extract using an excision wound model. An excision wound was created in rats in addition with *S. aureus* infection (0.5 MacFarland standard/1.5 x 10^8 CFU/mL) induced for 24 hours. Thereafter, leaf extract of *A. Nervosa* was applied topically at the dose of 100 mg/kg and 1000 mg/kg and 2% w/w Mupirocin ointment was applied as a positive control at 10 mg/kg and rats were subjected to evaluation of wound surface area (mm), percentage (%) of wound contraction, bacteriological load in wound surface (CFU/mL), and its microscopic examination.

A. Nervosa, a perennial climbing plant. It is known for its diverse health benefits, including antimicrobial, anti-inflammatory, and tissue-regenerating properties. The plant's leaves, rich in bioactive compounds like β-sitosterol and quercetin, are particularly effective in promoting wound healing. Topical application of its leaf extract accelerates tissue regeneration, reduces inflammation, and inhibits microbial growth, making it a promising agent for faster and more efficient wound recovery [5, 6].

The present study demonstrated the effects of *A. Nervosa* leaf extract on wound surface area over time. Consistent with previous findings, [8], showed that topical application of ethanolic *A. Nervosa* leaf extract led to a significantly faster reduction in wound surface area compared to controls. The effect was more pronounced in topically treated groups than orally treated ones, and especially notable in diabetic rats where healing is typically delayed. The study concluded that *A. Nervosa* leaf extract accelerates wound contraction and promotes faster epithelization, supporting its traditional use in wound healing. [27] Concluded that the wound healing activity is attributed to the presence of alkaloids, flavonoids, triterpenoids, saponins, tannins, and steroids in the extract, which contributes to anti-inflammatory and antimicrobial effects, further supporting rapid wound closure and tissue regeneration. In the current study, *A. Nervosa* leaf extract demonstrated a significant acceleration of wound healing, as evidenced by the progressive reduction in mean wound surface area over 22 days. Treatment with both 100 mg/kg (G3) and 1000 mg/kg (G4) doses resulted in statistically significant wound contraction compared to the control group of dose 0 mg/kg (G1) at multiple time points, this consistent performance not only hastened wound contraction but also sustained its improvement.

Interestingly, while the 10 mg/kg group (G2) (2% w/w Mupirocin ointment) showed observable improvements in wound surface area, especially during the initial phase (days 2–10), its effects were less consistent and did not achieve the same degree of statistical or biological significance as the *A. Nervosa* leaf extract. These findings suggest that *A. Nervosa* leaf extract may possess some potent bioactive compounds capable of promoting wound closure more effectively than conventional treatment in certain conditions. The extract's ability to enhance healing may be attributed to anti-inflammatory, antimicrobial, and pro-angiogenic properties, thereby collectively accelerating tissue repair and regeneration.

We have also investigated the effect of *A. Nervosa* leaf on the percent wound contraction and its healing potential. As per the previously conducted studies, [8] also concluded that topical application of the extract significantly increased wound contraction percentage compared to controls, especially in diabetic rats where healing is delayed. The extract promoted faster wound closure and epithelization, confirming its dose-dependent wound-healing efficacy. Histological improvements correlated with enhanced contraction rates [28]. Research also showed that *A. Nervosa* extracts significantly increased wound contraction rate, tensile strength, and hydroxyproline content (a collagen marker), indicating enhanced wound healing quality and speed. In our study, in the earliest phase of treatment, a slight increase in wound size was observed in some groups, which reflects the natural inflammatory stage that is essential for initiating wound healing. However, as the days progressed, particularly from day 4 onward, a clear pattern of improved wound contraction was seen in animals treated with *A. Nervosa*. Both the 100 mg/kg (G3) and 1000 mg/kg (G4) doses promoted a faster and more consistent closure of wounds compared to the control group (G1). This steady progress highlights the extract's ability to guide the healing process through critical early and middle phases, where timely regulation is most important. While the standard 10 mg/kg group (G2) (2% w/w Mupirocin ointment) provided some early improvement, it did not match the consistent wound closure achieved by *A. Nervosa*. As healing advanced toward day 22, all groups naturally showed a slowing down of wound contraction, marking the final stage of repair. These findings suggest that *A. Nervosa* does more than simply close wounds, it supports and harmonizes the body's own healing mechanisms, helping to balance inflammation, encourage tissue growth, and strengthen repair.

We further investigated on the controlling bacterial contamination at the wound site. As found in the earlier findings, [29], investigated alcoholic and aqueous extracts of A. *Nervosa* leaves against multiple bacterial strains, including *S. aureus*, *P. aeruginosa*, and *E. coli*. Their results showed clear antibacterial activity, with inhibition zones increasing with higher extract concentrations, indicating a dose-dependent effect [30], compared the antimicrobial activity of ethanolic extracts of *A. Nervosa* leaves with other medicinal plants. The study found that all ethanolic extracts, including that of *A. Nervosa*, produced significant inhibition zones against tested bacteria, with activity comparable to standard antibiotics. The results were consistent across repeated experiments and reflected a concentration-dependent inhibition [31], reported that different solvent extracts of *A. Nervosa* leaves possess antibacterial activity, and the degree of inhibition varied with extract concentration and solvent used, further supporting dose-dependency [32]. Revealed that the antimicrobial activity is likely due to the presence of flavonoids, alkaloids, saponins, and tannins, which are known for their bactericidal properties. In the current study, on the first day of observation, all groups showed a similarly high level of bacterial load, confirming that the starting conditions were uniform. As healing progressed, a remarkable reduction in bacterial count was observed in the groups treated with *A. Nervosa* leaf extract, particularly at the doses of 100 mg/kg (G3) and 1000 mg/kg (G4). This decline was both steady and dose-dependent, with a significant decrease appearing as early as day 3 and continuing consistently through the later days of the experiment. While the standard 10 mg/kg group (G2) (2% w/w Mupirocin ointment) also helped reduce bacterial numbers, *A. Nervosa* leaf extract demonstrated a strong and sustained antimicrobial effect

across most of the study period. Although a slight variation was noted on day 17 at the higher dose, the overall trend clearly supports the role of *A. Nervosa* leaf extract in suppressing bacterial growth. These results suggest that the leaf extract either acts directly by inhibiting microbial proliferation or indirectly by creating a healthier wound environment that resists secondary infections. Through this antimicrobial action, *A. Nervosa* leaf extract not only accelerates wound healing but also preserves the integrity of newly forming tissue.

The investigation was further taken on, histopathological evaluation of wound healing efficacy of *A. Nervosa* leaf extract. Previous findings have demonstrated that, [8], demonstrated that topical application of ethanolic *A. Nervosa* leaf extract significantly promoted wound healing in both normal and alloxan-induced diabetic rats.

Histopathological analysis revealed enhanced epithelialization, increased collagen deposition, and improved granulation tissue formation in treated wounds compared to controls. The extract showed superior effects when applied topically versus orally. The presence of alkaloids, flavonoids, triterpenoids, saponins, and tannins contributed to these effects by modulating inflammation and promoting tissue regeneration [28], showed that *A. Nervosa* extracts significantly increased wound contraction rate, tensile strength, and hydroxyproline content (a marker of collagen), indicating improved histological wound repair. In the current study, the histopathological analysis revealed that *A. Nervosa* leaf extract, particularly at doses of 100 mg/kg (G3) and 1000 mg/kg (G4), promoted efficient wound healing through several key biological activities. The anti-inflammatory properties of the extract likely played a central role in controlling inflammatory responses, which were evident in the reduced inflammatory cell infiltration observed in G3 and G4 groups. This control of inflammation allowed for more regulated tissue regeneration, as indicated by clear re-epithelialization, collagen deposition, and the growth of hair follicles. The observed neovascularization, or formation of new blood vessels, suggests that *A. Nervosa* leaf extract enhanced angiogenesis, providing essential nutrients and oxygen to the healing tissue. Additionally, the extract's ability to stimulate fibroplasia and collagen synthesis contributed to a more organized extracellular matrix, aiding in wound closure and strengthening tissue integrity. Moreover, the antimicrobial activity of the extract likely reduced bacterial load, preventing infections that could otherwise complicate healing and lead to severe ulceration. All this collectively promoted a balanced healing process, with minimal epithelial disruption and controlled wound severity. In contrast, the control group of dose 0 mg/kg (G1) group exhibited impaired healing, with persistent inflammation, irregular fibroplasia, and severe ulceration, highlighting the superior healing potential of *A. Nervosa* leaf extract.

5. Conclusion

In conclusion, the present study demonstrates the potential of *A. Nervosa* leaf extract in promoting wound healing through its antimicrobial and healing properties. The results show that topical application of the leaf extract significantly reduced wound surface area, enhanced wound contraction, and improved tissue regeneration in comparison to controls. The extract's effectiveness was notably more pronounced in higher doses, where it supported accelerated epithelization, increased collagen deposition, and reduced bacterial contamination at the wound site. Additionally, histopathological analyses confirmed the extract's role in regulating inflammation, promoting fibroplasia, and stimulating angiogenesis, contributing to more efficient and structured wound healing. However, some limitations of the study include the relatively small sample size and the focus on animal models, which may not fully reflect the complexities of human wound healing. Future studies should include a broader range of doses, and clinical trials to further validate these findings in human subjects. Additionally, the specific molecular mechanisms through which *A. Nervosa* exerts its therapeutic effects require deeper investigation to enhance our understanding of its full potential. Concisely, *A. Nervosa* leaf extract holds promise as an effective alternative in wound care, offering both antimicrobial and tissue-regenerating benefits. Further research is necessary to optimize its clinical applications and explore its long-term effects in diverse healing conditions.

6. Acknowledgement

This study was conducted by Jai Research Foundation, Valvada, and Gujarat, India and did not receive any specific grant from funding agencies in the public, commercial, or not-for-profit sectors.

7. Conflict of interest

We wish to confirm that there are no known conflicts of interest associated with this publication, and there has been no significant financial support for this work that could have influenced its outcome.

References

1. Cioce A, Cavani A, Cattani C, Scopelliti F. Role of the skin immune system in wound healing. Cells. 2024;13(7):624. DOI:10.3390/cells13070624.
2. Strbo N, Yin N, Stojadinovic O. Innate and adaptive immune responses in wound epithelialization. Adv Wound Care (New Rochelle). 2014;3(7):492-501. DOI:10.1089/wound.2012.0435.
3. Geng C, *et al*. Achieving clearance of drug-resistant bacterial infection and rapid cutaneous wound regeneration using an ROS-balancing-engineered heterojunction. Adv Mater. 2024;36(16). DOI:10.1002/adma.202310599.
4. Martin P, Pardo-Pastor C, Jenkins RG, Rosenblatt J. Imperfect wound healing sets the stage for chronic diseases. Science. 2024;386(6726). DOI:10.1126/science.adp2974.
5. Lawand PR, Shimpale VB. Revision of the genus *Argyreia* (Convolvulaceae) from India. J Indian Assoc Angiosperm Taxon. 2024;34(5):336-395.
6. Krishnamurthy K, *et al.* Green synthesis and evaluation of antimicrobial, antioxidant, anti-inflammatory, and antidiabetic activities of silver nanoparticles from *Argyreia nervosa* leaf extract: an *in vitro* study. J King Saud Univ Sci. 2023; 35(10):102955. DOI:10.1016/j.jksus.2023.102955.
7. Padhi M, Mahapatra S, Panda J, Mishra NK. Traditional uses and psychopharmacological aspects of *Argyreia nervosa*. J Adv Pharm Res. 2013; 4(1):23-32.
8. Singhal A, Gupta H, Bhati V. Wound healing activity of *Argyreia nervosa* leaves extract. Int J Appl Basic Med Res. 2011; 1(1):36-40.

DOI:10.4103/2229-516X.81978.
9. Sapkal KR, Patil VS, Taur RR. Green synthesis of silver nanoparticles using the leaf extract of *Argyreia nervosa* and antimicrobial studies. Int J Pharm Sci Res. 2024; 15(5).
10. Gupta DP. The Herbs. Vol. 8. 1st ed. Indore: Smt Prem Lata Gupta Prakashak; 2008.
11. Bhakuni DS, Goel AK, Jain S, Mehrotra BN, Srimal RC. Screening of Indian plants for biological activity. Part XIV. Indian J Exp Biol. 1990; 28(7):619-637.
12. Srivastava MC, Kant V, Tewari JP. Antiinflammatory activity of roots of *Argyreia speciosa* (Sumandrashokha). Mediscope. 1972; 15(2):219.
13. Azis H, Taher M, Susanti D, Zakaria Z. *In vitro* wound healing activity of *Sapium indicum* Willd. Leaf extracts. Afr J Tradit Complement Altern Med. 2015; 12(2):126-132. DOI:10.4314/ajtcam.v12i2.19.
14. Chummun I, Bekah D, Goonoo N, Bhaw-Luximon A. Assessing the mechanisms of action of natural molecules/extracts for phase-directed wound healing in hydrogel scaffolds. RSC Med Chem. 2021;12(9):1476-1490. DOI:10.1039/D1MD00100K.
15. Bittner Fialová S, Rendeková K, Mučaji P, Nagy M, Slobodníková L. Antibacterial activity of medicinal plants and their constituents in the context of skin and wound infections, considering European legislation and folk medicine: a review. Int J Mol Sci. 2021; 22(19):10746. DOI:10.3390/ijms221910746.
16. Mishra AP, Saklani S, Chandra S, Tiwari P. Total phenolics, flavonoids and antioxidant evaluation in the leaves of *Argyreia nervosa* Burm.f. Int J Pharm Sci Rev Res. 2015;32(2):34-37.
17. Goti D, Dasgupta S. A comprehensive review of conventional and non-conventional solvent extraction techniques. J Pharmacogn Phytochem. 2023;12(3):202-211. DOI:10.22271/phyto.2023.v12.i3c.14682.
18. Shevelev AB, *et al. In vivo* antimicrobial and wound-healing activity of resveratrol, dihydroquercetin, and dihydromyricetin against *Staphylococcus aureus*, *Pseudomonas aeruginosa*, and *Candida albicans*. Pathogens. 2020;9(4):296. DOI:10.3390/pathogens9040296.
19. D'Abadia PL, *et al.* Tissue healing changes on wounds in rats after treatment with *Hancornia speciosa* latex in cream-gel formulation. Acta Cir Bras. 2022;37(10). DOI:10.1590/acb371001.
20. Joshi BB, Chaudhari MG, Mistry KN, Dabhi B, Sanjay I. *In vitro* screening of antibacterial and antifungal activity of crude extract of *Argyreia nervosa*. Int J Pavement Res Technol. 2013;5(2):88-96.
21. Jerine I, Vishnu Priya V, Jayaraman S. Antidiabetic and antioxidant potential of ethyl iso-allocholate is mediated through insulin receptor/IRS-1/Akt/GLUT4 mediated pathways: *in vitro* and in silico mechanisms. Texila Int J Public Health. 2024.
22. Kamlungmak S, *et al.* Safety and biocompatibility of mupirocin nanoparticle-loaded hydrogel on burn wound in rat model. Biol Pharm Bull. 2021;44(11). DOI:10.1248/bpb.b21-00397.
23. Cai EZ, *et al.* Creation of consistent burn wounds: a rat model. Arch Plast Surg. 2014;41(4):317-324. DOI:10.5999/aps.2014.41.4.317.
24. Adhirajan N, Shanmugasundaram N, Shanmuganathan S, Babu M. Collagen-based wound dressing for doxycycline delivery: *in vivo* evaluation in an infected excisional wound model in rats. J Pharm Pharmacol. 2009;61(12):1617-1623. DOI:10.1211/jpp.61.12.0005.
25. Cardiff RD, Miller CH, Munn RJ. Manual hematoxylin and eosin staining of mouse tissue sections. Cold Spring Harb Protoc. 2014;2014(6).prot073411. DOI:10.1101/pdb.prot073411.
26. Alrouji M, *et al.* A simple *in vivo* method for evaluation of antibiofilm and wound healing activity using excision wound model in diabetic Swiss albino mice. Microorganisms. 2023;11(3):692. DOI:10.3390/microorganisms11030692.
27. Kumar BS, Gouda S, Mane S, Biradar A, Shivani S. Evaluation of anti-inflammatory and analgesic activity of *Argyreia nervosa* leaf extracts. Int J Nov Res Dev. 2023;8(5).
28. Jaiswal BS, Tailang M. Phytochemistry and pharmacological profile of traditionally used medicinal plant *Argyreia speciosa* (Linn. f.). J Drug Deliv Ther. 2018;8(5 Suppl):41-46. DOI:10.22270/jddt.v8i5-s.1937.
29. Yadav P, Yadav A, Gupta A, Mahajan S, Agnihotri RKA, Sharma R. Antibacterial activity of *Argyreia nervosa* Burm.f. against different strains of bacteria. Indian J Appl Res. 2014;4(7):443-445. DOI:10.15373/2249555X/July2014/140.
30. Modi AJ, Khadabadi SS, Farooqui IA, Ghorpade DS. Studies on antimicrobial activity of *Clerodendrum infortunatum*, *Argyreia nervosa* and *Vitex negundo*: a comparison. Der Pharm Lett. 2010;2(1):102-105.
31. Padhi M, Mahapatra S, Panda J. Antibacterial and antioxidant study of different solvent extracts of leaves of *Argyreia nervosa*. Pharma Sci Monit. 2015;6(2):248-255.
32. Modi AJ, Khadabadi SS, Farooqui IA, Deore SL. *Argyreia speciosa* Linn.f.: phytochemistry, pharmacognosy and pharmacological studies. Int J Pharm Sci Rev Res. 2010;2(2):1-8.