International Journal of Advanced Biochemistry Research

ISSN Print: 2617-4693
ISSN Online: 2617-4707
NAAS Rating (2026): 5.29
IJABR 2026; 10(1): 306-309
www.biochemjournal.com
Received: 03-11-2025
Accepted: 20-12-2025

Nitin Sharma
M.V.Sc. Scholar, Department of Veterinary Anatomy, College of Veterinary and Animal Science, Rajasthan University of Veterinary and Animal Sciences, Bikaner, Rajasthan, India

Pankaj Kumar Thanvi
Associate Professor and Head, Department of Veterinary Anatomy, College of Veterinary and Animal Science, Rajasthan University of Veterinary and Animal Sciences, Bikaner, Rajasthan, India

Ashok Dangi
Assistant Professor, Department of Veterinary Anatomy, College of Veterinary and Animal Science, Rajasthan University of Veterinary and Animal Sciences, Bikaner, Rajasthan, India

Devendra Singh
Assistant Professor, Department of Veterinary Anatomy, College of Veterinary and Animal Science, Rajasthan University of Veterinary and Animal Sciences, Bikaner, Rajasthan, India

Aruna Panwar
Ph.D. Scholar, Department of Veterinary Anatomy, College of Veterinary and Animal Science, Rajasthan University of Veterinary and Animal Sciences, Bikaner, Rajasthan, India

Corresponding Author:
Nitin Sharma
M.V.Sc. Scholar, Department of Veterinary Anatomy, College of Veterinary and Animal Science, Rajasthan University of Veterinary and Animal Sciences, Bikaner, Rajasthan, India

Histochemical studies of the tongue of buffalo (*Bubalus bubalis*)

Nitin Sharma, Pankaj Kumar Thanvi, Ashok Dangi, Devendra Singh and Aruna Panwar

DOI: https://www.doi.org/10.33545/26174693.2026.v10.i1d.6928

Abstract
The present investigation was carried out on 20 recently died, apparently healthy adult buffalo which were free from any pathological condition of tongue from Municipal Slaughter House, Bikaner. The histochemical reactions were mainly observed in the epithelium and submucosal glands. A strong positive PAS reaction was seen in the stratum corneum and endothelium of blood vessels whereas the lamina propria showed a negative PAS reaction. The PAS reactivity was negative in saliva-treated sections. Epithelium showed moderate reactions to acidic mucopolysaccharides (Alcian blue at pH-1.0). Some secretory units had weaker PAS Alcian Blue positive reaction and took lighter blue stain (at pH 1.0) while some had strong positive reaction and took dark blue stain (at pH 2.5). In Dane's and Ayoub Skhlar stains, Stratum corneum took brilliant red colour and a reddish orange colour respectively, suggesting a higher concentration of keratin and pre-keratin.

Keywords: Histochemical, stratum corneum, keratin and pre-keratin

Introduction
The buffalo (*Bubalus bubalis*), often known as the domestic water buffalo or Asian water buffalo, that originated in the Indian subcontinent and South-east Asia and was domesticated about 6,300 years ago. (https://en.wikipedia.org/wiki/Water_buffalo).
According to the 2019 census, there are 109.85 million buffalo in India. Since the 2012 census, the total buffalo population has increased by 1.1%. The contribution of buffaloes to the total livestock is about 20.5%. According to the 2019 census, Rajasthan has 13.7 million buffaloes, increased by 5.38% since the 2012 census (20th livestock census-vikaspedia).
According to the 2019 census, water buffaloes produced 91.82 million tons of milk, or nearly half of all the milk produced in India. (https://en.wikipedia.org/wiki/Buffalo_milk).
About 43% of the world's buffalo meat is produced in India, with Uttar Pradesh producing the most, followed by Andhra Pradesh and Maharashtra. (https://en.wikipedia.org/wiki/Buffalo_meat).
The tongue is one of the most useful and significant organs of the body. According to the needs and habits of the animal, its structure varies from species to species. The tongue is the main organ for prehension and mastication of food, with a highly muscular structure. The buffalo's tongue helps with activities like sucking and eating. The tongue is essential for a newborn buffalo's survival because it helps build up pressure in the mouth so the newborn can properly suck. The clinical examination of the tongue aids in the diagnosis of a number of illnesses including foot-and-mouth disease, bluetongue virus (BTV), epizootic haemorrhagic disease (EHD) and even certain cases of poisoning etc. The present study was aimed to investigate the structure of the tongue of buffalo to justify the importance and essentiality in the body.

Materials and Methods
The tongue samples were collected from 20 recently dead, apparently healthy adult buffaloes which were free from any pathological condition of the tongue from Municipal Slaughter House, Bikaner. The investigation of the organs was carried out in the Department of Veterinary Anatomy, CVAS, RAJUVAS, Bikaner.

The collected samples were used for histochemical study.

Histochemical studies

For these small pieces (2-3 mm size) of representative areas of tongue were collected from identical sites and fixed in 10% neutral buffered formalin or Bouin's fluid for 24-72 hours and 18-24 hours respectively, followed by overnight washing in running tap water, dehydration in ascending order of alcohol (50%, 70%, 90% and then Absolute Alcohol-I, II & III), clearing in chloroform and finally embedding in paraffin wax. Paraffin blocks were prepared, numbered and stored at 4 °C. Five-to-six-micron thick sections were cut by using semi-automatic microtome then sections were mounted of the on albumenized slides and drying of the section and then staining were done. McManus's method with saliva (PAS) for glycogen (Singh and Sulochana, 1997) [11], Mc Manus's method-PAS for glycogen (Singh and Sulochana, 1997) [11], PAS-Alcian blue method pH 1.0 for mucous substances (Luna, 1968) [6], PAS-Alcian blue method pH 2.5 for mucous substances (Luna, 1968) [6], Ayoub-Shklar method for keratin and pre-keratin (Luna, 1968) [6], Dane's method for pre-keratin, keratin and mucin (Luna, 1968) [6], Alcian blue method pH 1.0 for sulphated mucopolysaccharides (Luna, 1968) [6].

Result and Discussion

The histochemical reactions were mainly observed in the epithelium and submucosal glands.

Periodic acid-Schiff (PAS) reaction for glycogen

Mild PAS reactivity was seen in the mucous epithelial cells which were stained light purplish rose colour. In disagreement to this, the mucous acini showed a strong Schiff reaction in the finding of Parida and Das (1991) [8] in cattle, buffalo, sheep and goat while the serous acini of Von Ebner's glands showed a moderate PAS positive reaction in the finding of Biradar and Ramkrishna (2000) [3] in sheep (Fig. 1).

A strong positive PAS reaction was seen in the stratum corneum and endothelium of blood vessels whereas the lamina propria showed a negative PAS reaction. The stratum corneum showed purplish rose colour which indicates positive PAS reaction. In the duct epithelial cells, which stained lighter in colour, the PAS reaction was less prominent. A positive PAS reaction was noted in basement membrane of mucous gland. The PAS reactivity was negative in the saliva-treated section. However, according to Narasimhan *et al.* (1999) [7] serous cells showed no evidence of Schiff reaction (Fig. 1).

Alcian blue reaction at pH-1.0 (Weakly acidic sulfated Mucous substances give positive reaction)

Epithelium showed moderate reactions to acidic mucopolysaccharides. Lamina propria showed negative response to acidic mucopolysaccharides. A strong reactivity was seen in the mucous epithelial cells and stained dark blue colour which indicates the presence of acidic mucopolysaccharides. The duct epithelial cells showed less reactivity to acidic mucopolysaccharides and gave light blue color (Fig. 4).

PAS Alcian Blue reaction for mucous substances

Regarding PAS Alcian Blue (pH 1.0 and 2.5) staining, the positive PAS Alcian Blue reaction was observed at different intensities in both mucous and serous secretory units of sero-mucous glands. This finding was in partial harmony with the finding of El-Bakary and Abumandour (2017) [4] in Egyptian water buffalo. Some secretory units had weaker PAS Alcian Blue positive reaction and took lighter blue stain (At pH 1.0) while some had strong positive reaction and took dark blue stain (At pH 2.5). The ducts showed either a weak or absent PAS Alcian Blue reactivity (Figs. 2, 3 and 6).

Ayoub-Shklar and Dane's method for Keratin and Pre-Keratin reaction

In Dane's stain, Stratum corneum took on a brilliant red colour, suggesting the presence of a greater amount of keratin and pre-keratin (Fig. 5) whereas in Ayoub Skhlar stain, stratum corneum displayed a reddish orange colour, suggesting a higher concentration of keratin and pre-keratin (Figs. 7 and 8).

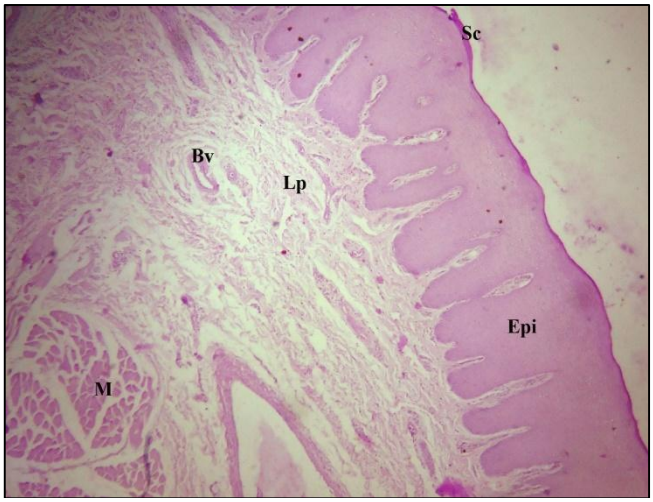

Fig 1: Photomicrograph of tongue of buffalo showing positive PAS reaction.
Sc-Stratum corneum, Epi.-Epithelium, Sc-Stratum corneum, Lp-Lamina propria, Bv-Blood vessels
(Mc Manus method for glycogen (PAS) stain, 40X)

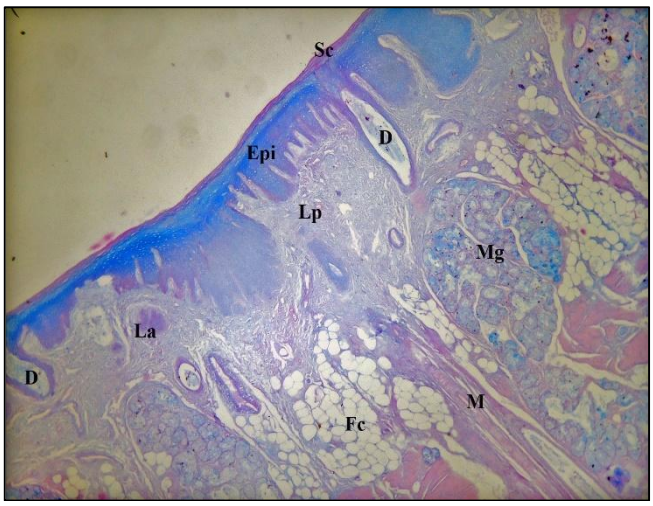

Fig 2: Photomicrograph of tongue of buffalo showing positive PAS-Alcian blue reaction. Mg-Mucosal gland, La-lymphatic aggregation, M-Muscle,
D-Duct of gland, Fc-Fat cells, Epi.-Epithelium, Sc-Stratum corneum,
Lp-Lamina propria
(PAS-Alcian blue stain for mucosubstances pH 1.0, 40X)

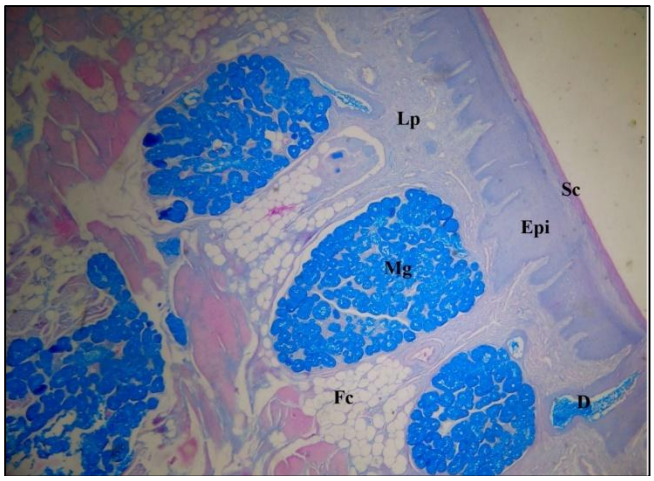

Fig 3: Photomicrograph of tongue of buffalo showing positive PAS-Alcian blue reaction. Mg-Mucosal gland, D-Duct of gland, Fc-Fat cells,
Epi.-Epithelium, Sc-Stratum corneum, Lp-Lamina propria
(PAS-Alcian blue stain for mucosubstances pH 2.5, 40X)

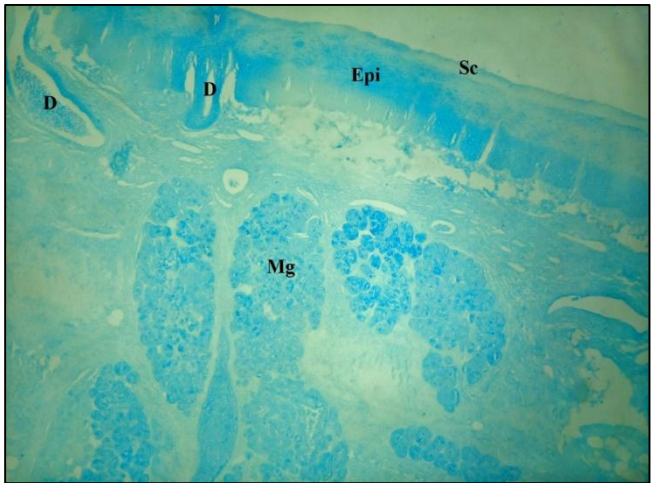

Fig 4: Photomicrograph of tongue of buffalo showing positive reaction for
Alcian blue pH 1.0 for sulfated mucosubstances. Mg-Mucosal gland,
Sc-Stratum corneum, D-Duct of gland, Epi.-Epithelium
(Alcian blue pH 1.0 stain, 40X)

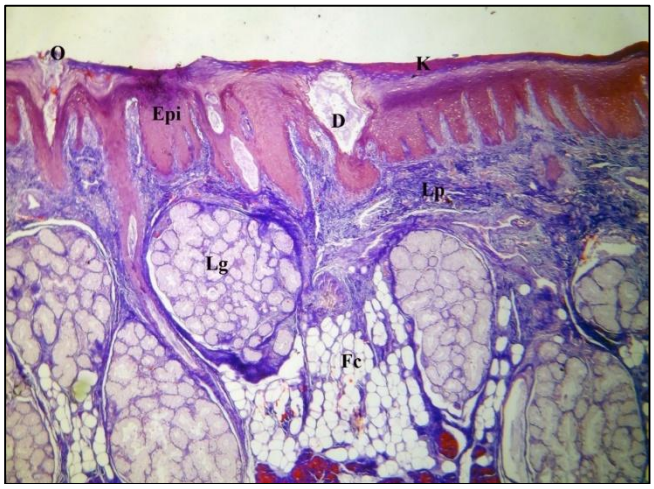

Fig 5: Photomicrograph of tongue of buffalo showing positive mucin reaction in lingual glands. Lg-Lingual glands, D-duct of glands, O-Opening of duct of gland, Fc-Fat cells, Epi.-Epithelium, K-Keratin, Lp-Lamina propria.
(Dan's method for keratin, prekeratin and mucin, 40X)

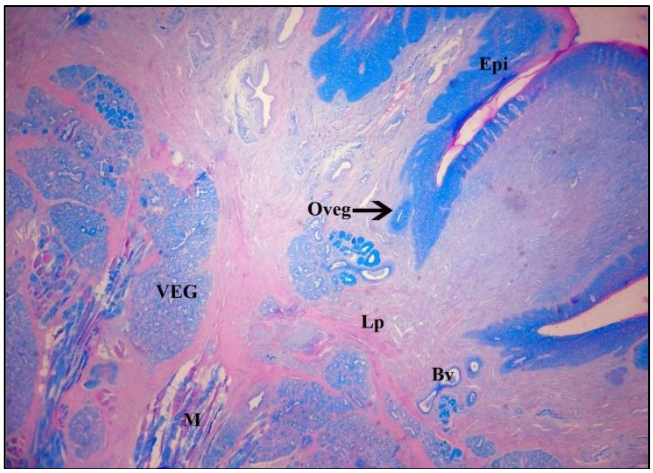

Fig 6: Photomicrograph of tongue of buffalo showing positive reaction for
PAS-Alcian blue for mucosubstances. Epi.-Epithelium, M-Muscles,
Oveg-Opening of Von Ebner's gland, VEG-Von Ebner's gland, Lp-Lamina propria, Bv-Blood vessels
(PAS-Alcian blue stain for mucosubstances pH 1.0, 40x)

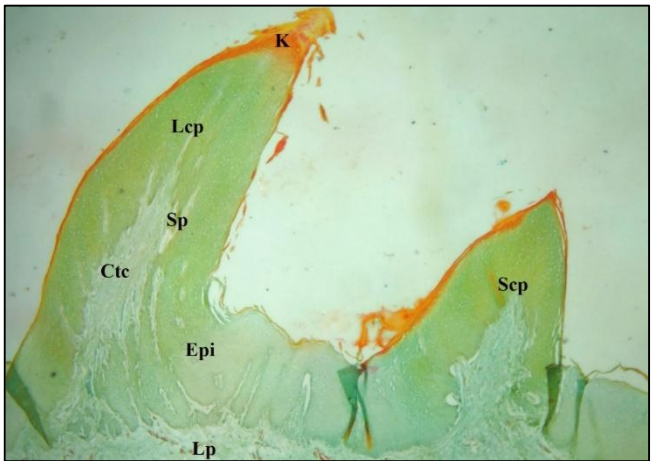

Fig 7: Photomicrograph of dorsal surface of tongue of buffalo showing conical papillae.
Lcp-Large conical papillae, Scp-Small conical papillae, Sp-Secondary papillae, Epi.-Epithelium, Ctc-Connective tissue core, K-Keratin, Lp-Lamina propria
(Ayoub-Shklar method for keratin and prekeratin,100x)

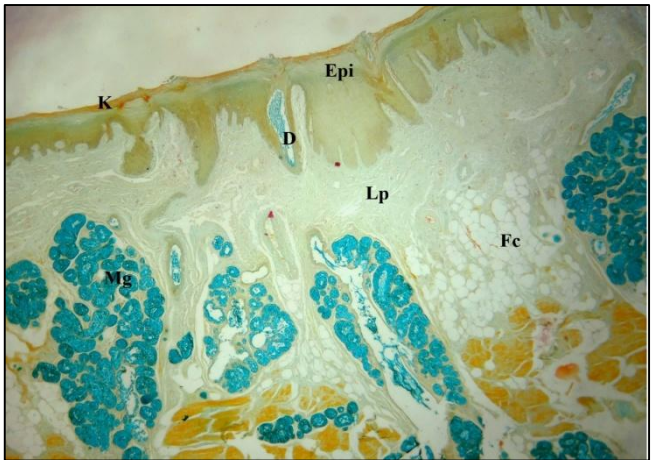

Fig 8: Photomicrograph of tongue of buffalo showing positive reaction for keratin. K-Keratin, D-Duct of gland, Mg-Mucosal gland, Fc-Fat cells,
Epi.-Epithelium, Lp-Lamina propria
(Ayoub-Skhlar method for keratin and prekeratin, 40X)

Conclusion

The histochemical study of the buffalo tongue using PAS, PAS-Alcian Blue, Alcian Blue, Ayoub-Shklar and Dane's staining revealed significant findings regarding the distribution of glycogen, mucopolysaccharides, keratin and pre-keratin. The epithelium of the tongue showed moderate reactions to acidic mucopolysaccharides. Higher concentration of keratin and pre-keratin was noticed in stratum corneum layer of tongue.

Acknowledgments

The authors are highly thankful to Dean, College of Veterinary and Animal Science, Bikaner, RAJUVAS, Bikaner, Rajasthan for providing all necessary facilities to carry out research work. The authors are also thankful to all members of the Department of Anatomy for their help during the accomplishment of this work.

References

1. Annual report (2020-21). Agricultural and Processed Food Products Export Development Authority (APEDA), Government of India. Available from: https://apeda.gov.in/apedawebsite/SubHead_Products/Buffal_Meat
2. Anonymous. 20th Livestock Population Census. Department of Animal Husbandry and Dairying, Ministry of Agriculture and Farmers Welfare, Government of India; 2019.
3. Biradar RB, Ramkrishna V. Histology and histochemistry of von Ebner's and lingual glands in sheep and goat. Indian J Anim Sci. 2000;70(9):906-908.
4. El-Bakary NER, Abumandour MMA. Morphological studies of the tongue of the Egyptian water buffalo (*Bubalus bubalis*) and their lingual papillae adaptation for its feeding habits. Anat Histol Embryol. 2017;46(5):1-13.
5. Jain S. A comparative histological and histochemical study of mammalian tongue. M.S. Thesis. Jaipur: University of Rajasthan; 1975.
6. Luna LG, editor. Manual of histologic staining methods of the Armed Forces Institute of Pathology. 3rd ed. London: McGraw-Hill Company; 1968. p. 87-88, 94-95.
7. Narasimhan E, Gopinath S, Rao KVS, Rao TSCS. Histological studies on the lingual glands of the goat (*Capra hircus*). Indian J Vet Anat. 1999;11:115-118.
8. Parida S, Das LN. Histomorphology of the minor salivary glands of domestic ruminants. Indian J Vet Anat. 1991;3:77-83.
9. Roy KS, Singh J, Singh B, Saigal RP. Histoenzymic study on vallate papillae and intrinsic muscle in the tongue of goat. Indian J Vet Anat. 1991;3:45-45.
10. Singh J, Roy KS, Singh B, Saigal RP. Histoenzymic study of the glands in tongue of goat. Indian J Anim Sci. 1992;63:233-235.
11. Singh UB, Sulochana SA. Handbook of histological and histochemical technique. Hyderabad: Premier Publishing House; 1997. p. 8-57.