International Journal of Advanced Biochemistry Research

**ISSN Print:** 2617-4693
**ISSN Online:** 2617-4707
NAAS Rating (2025): 5.29
IJABR 2025; 9(10): 351-355
www.biochemjournal.com
Received: 26-08-2025
Accepted: 29-09-2025

**Dr. S Dhilleswara Rao**
Assistant Professor, Department of Veterinary Anatomy, College of Veterinary Science, Sri Venkateswara Veterinary University, Garividi, Vizianagaram, Andhra Pradesh, India

**Dr. P Jagapathi Ramayya**
Associate Professor Dean, College of Veterinary Science, Sri Venkateswara Veterinary University, Tirupati, Andhra Pradesh, India

**Dr. M Santhi Lakshmi**
Professor, Department of Veterinary Anatomy, College of Veterinary Science, Sri Venkateswara Veterinary University, Tirupati, Andhra Pradesh, India

**Dr. RV Suresh Kumar**
Professor, University Head, Department of Veterinary Radiology and Surgery, College of Veterinary Science, Sri Venkateswara Veterinary University, Tirupati, Andhra Pradesh, India

**Dr. B Rambabu Naik**
Professor, University Head, Department of Veterinary Physiology, College of Veterinary Science, Sri Venkateswara Veterinary University, Tirupati, Andhra Pradesh, India

**Corresponding Author:**
**Dr. S Dhilleswara Rao**
Assistant Professor, Department of Veterinary Anatomy, College of Veterinary Science, Sri Venkateswara Veterinary University, Garividi, Vizianagaram, Andhra Pradesh, India

# Electronmicroscopic studies on endocrine pancreas of buffalo, sheep and goat

**S Dhilleswara Rao, P Jagapathi Ramayya, M Santhi Lakshmi, RV Suresh Kumar and B Rambabu Naik**

**DOI:** https://www.doi.org/10.33545/26174693.2025.v9.i10e.6041

**Abstract**
The present study compared the ultrastructure of pancreatic islets of Langerhans in buffalo, sheep, and goat, focusing on α, β, δ, and PP cells. The islets were irregularly distributed among acini and varied in size. In buffalo, α-cells were peripheral with highly electron-dense granules (0.20-0.61 µm) surrounded by distinct halos, abundant rER, and prominent mitochondria, indicating high secretory activity. In contrast, sheep α-cells had fewer, less dense granules (0.18-0.32 µm) with indistinct halos, while goat α-cells possessed the smallest granules (0.12-0.18 µm) without halos. Buffalo β-cells, centrally located, contained dense granules (0.24-0.47 µm) with distinct halos and well-developed Golgi apparatus, whereas sheep β-cell granules were larger (0.30-0.47 µm) but less electron dense, and goat β-cells showed smaller, heterogeneous granules (0.20-0.29 µm). δ-cells were peripheral in all species; however, goat δ-cells exhibited unique dendrite-like cytoplasmic projections with lozenge-shaped granules (0.14-0.25 µm). PP cells were fewer in number, smallest in size, and showed scarce organelles across all species. Overall, buffalo exhibited the most metabolically active islet cells, while goats showed structural adaptations suggesting intercellular communication.

**Keywords:** Ultrastructure, endocrine pancreas, α-cell, β-cell, δ-cell, and PP cell

## Introduction
The islets of Langerhans of the pancreas comprise diverse endocrine cell types exhibiting species-specific ultrastructural variations. Lacy (1957, 1961) [6] first described α, β, and C-cells in guinea pig and dog, noting rod-shaped β-granules surrounded by halos. Caramia *et al.* (1965) [3] identified A, B, C, and D-cells in guinea pig based on granule size, while Sato *et al.* (1966) [15] reported α, β, δ, and clear cells in pig, cat, and dog, with α-cells showing dense spherical granules and β-cells possessing rod or V-shaped granules. Legg (1967) [8] described β and δ-cells in cat pancreas, δ-cells having urn-shaped vesicles. Forssmann (1976) observed A, B, D, G, and S-cells in horse, and Weir and Like (1980) [17] reported α, β, δ, and PP-cells in bovine islets. Subsequent studies in camel (Masaad, 2007; Hafez and Zaghloul, 2017) [11, 5], goat (Meshram *et al.,* 2015) [12], and mouse (Pfeifer *et al.,* 2015) [14] revealed comparable endocrine organization with species-specific granule size, density, and halo variations, reflecting functional and metabolic diversity among mammals. But literature is scanty in comparative ultrastructure studies on endocrine pancreas of buffalo, sheep and goat. Therefore, the present study was undertaken to conduct a comparative ultrastructural investigation on endocrine pancreas of the buffalo, sheep and goat.

## Materials and Methods
The present study was conducted on pancreas of domestic animals i.e 15 adult buffalo, 19 sheep, and 18 goats of either sex. The tissue samples of pancreas of buffalo, sheep and goat were collected immediately after their slaughter at municipal slaughter house, Proddatur and Tirupati.
For ultrastructural studies, the tissue samples were collected with 2 mm thickness into vials and fixed immediately in 3% of glutaraldehyde in 0.1 M phosphate buffer (pH 7.2) for 24 hrs at 4 °C and post fixed in 2% aqueous osmium tetroxide for 4 hrs. Further, standard protocol was followed for processing of tissues for transmission electron microscopy (Bancroft and Gamble, 2008) [1].

Sectioning and TEM studies were carried out at Electron Microscopy Lab, Department of Neuropathology, NIMHANS, Bangalore.

## Results

The ultrastructural observations of the endocrine portion of the pancreas revealed species-specific variations among buffalo, sheep, and goat. The islets of Langerhans were irregularly distributed between the pancreatic acini and varied in size as small, medium, or large, with a few scattered endocrine cells observed individually within the parenchyma. Each islet was composed of α (alpha), β (beta), δ (delta), and PP (pancreatic polypeptide) cells, showing distinct ultrastructural differences among the species (Figs. 1-10).

In buffalo, the α-cells were predominantly located at the periphery of the islets, each with a spherical or oval nucleus having evenly distributed euchromatin and peripheral heterochromatin. The cytoplasm contained numerous, highly electron-dense secretory granules, each surrounded by a narrow, less dense halo (Fig. 1). These granules were circular to oval and varied from 0.20-0.61 µm in diameter, with centrally or eccentrically placed dense cores (Fig. 1). Most of the granules were enclosed by thin complete membranes, while a few showed incomplete or absent membranes. The mitochondria were abundant, rounded to elongated, and distributed throughout the cytoplasm, occasionally located between the α-granules. The rER was abundant, and the Golgi apparatus was moderately developed around the nucleus. The β-cells were the most numerous and located centrally in the buffalo islets (Fig. 2). They contained spherical nuclei with distinct nucleoli and evenly distributed chromatin. Numerous secretory granules of variable density and size (0.24-0.47 µm) were observed, some showing distinct electron-dense cores with peripheral halos, while others appeared empty (Fig. 2). The mitochondria were abundant, circular to elongated, and concentrated mainly around the nucleus. The Golgi apparatus was extensive, while the rER was sparse. The δ-cells were fewer and located peripherally, with ovoid nuclei and dense cytoplasm containing small granules (0.12-0.41 µm) surrounded by clear halos (Fig. 3). These cells showed numerous mitochondria, moderate Golgi stacks, and scarce rER. The PP cells were the smallest and least numerous, also located peripherally. They had irregular nuclei with prominent heterochromatin and contained very few, moderately electron-dense secretory granules smaller than those of the δ-cells. The mitochondria, Golgi apparatus, and rER were scarce in these cells, indicating reduced secretory activity.

In sheep, the islets of Langerhans were interspersed between the acini and separated by narrow gaps and tight junctions. The α-cells were located at the periphery and appeared irregularly triangular with spherical nuclei containing condensed chromatin. These cells contained few secretory granules (0.18-0.32 µm) with indistinct halos. The mitochondria were numerous and varied in shape i.e circular, oval, or elongated, while the rER and Golgi apparatus were sparse (Fig. 4). The β-cells were centrally placed and more numerous than the other cell types. Their nuclei were spherical or oval with distinct nucleoli and surrounded by double-layered nuclear membranes containing pores. The adjacent β-cells showed smooth plasma membranes with narrow intercellular spaces and gap junctions. The cytoplasm contained numerous oval or spherical secretory granules (0.30-0.47 µm), which were less electron dense and more heterogeneous than those of α-cells, and most were surrounded by distinct membrane-bound halos (Fig. 5). Numerous mitochondria were distributed throughout the cytoplasm, while cup-shaped Golgi apparatus and sparse rER were located near the nucleus. The δ-cells were fewer and located at the periphery, extending neuron-like cytoplasmic processes from the islet core (Fig. 6). These cells contained diamond-shaped granules (0.11-0.19 µm), most of which were moderately electron dense, with few showing intense density. The mitochondria, Golgi apparatus, and rER were relatively few. The PP cells were small, peripheral, and contained spherical, electron-dense granules (0.11-0.19 µm) with membrane-bound halos (Fig. 7). They exhibited scarce mitochondria and poorly developed rER and Golgi apparatus.

In goat, the α-cells were located at the periphery of the islets and were irregularly triangular with oval nuclei showing condensed chromatin (Fig. 8). These cells contained very few cytoplasmic granules (0.12-0.18 µm) that lacked halos. Numerous mitochondria of circular, oval, and elongated shapes were present, but the rER and Golgi apparatus were scarce. The β-cells were numerous and centrally positioned, having irregularly triangular to oval shapes with spherical nuclei and prominent nucleoli (Fig. 8). The cytoplasm contained numerous moderately electron-dense secretory granules (0.20-0.29 µm) that were oval to spherical and mostly enclosed by membrane-bound halos, though some lacked membranes. The mitochondria were abundant and varied in shape i.e dumbbell, elongated, circular, or oval distributed throughout the cytoplasm, with moderate Golgi apparatus and scarce rER. The δ-cells were fewer, peripheral, and exhibited dendrite-like cytoplasmic projections extending toward the central islet and surrounding capillaries. They contained urn-or lozenge-shaped secretory granules (0.14-0.25 µm), mostly moderately electron dense and localized to one side of the cell (Fig. 9). The mitochondria, Golgi apparatus, and rER were few in number. The PP cells were small and least numerous, present at the periphery of the islets (Fig. 10). Their cytoplasm contained few moderately electron-dense granules without halos, with sparse mitochondria, rER, and Golgi apparatus, and occasional inclusion bodies.

Comparatively, buffalo islets exhibited the most metabolically active endocrine cells, characterized by larger and denser secretory granules, abundant mitochondria, and well-developed Golgi apparatus especially in α and β-cells. Sheep islets showed larger β-granules but with lower electron density and moderately developed cytoplasmic organelles, while goat islets exhibited smaller and fewer granules, reduced organellar complexity, and distinctive δ-cells with dendritic processes suggesting enhanced intercellular communication. Overall, the ultrastructural differences reflected species-specific variations in endocrine activity and metabolic adaptations among buffalo, sheep, and goat.

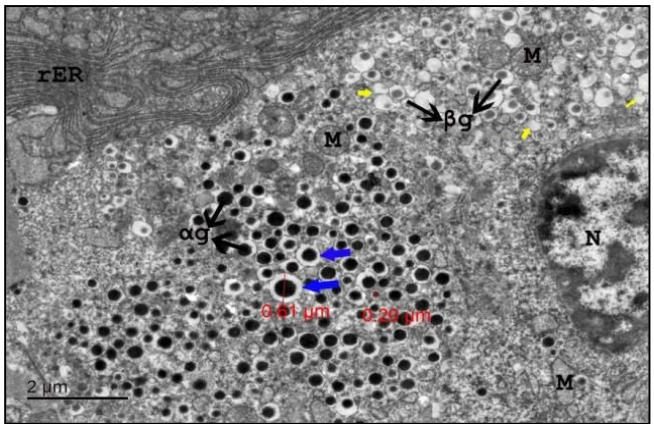


**Fig 1:** Electronmicrograph showing α and β granules of islet of Langerhans in pancreas of buffalo. x 2000
rER-Rough endoplasmic reticulum
N-Nucleus
βg-Beta granules
αg-Alpha granules
M-Mitochondria
Blue arrow-Membrane bound "halo", around the granule
Yellow arrow-Granules without "halo"

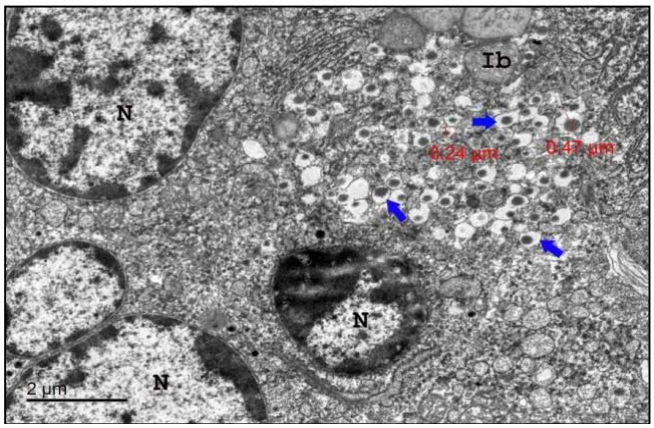


**Fig 2:** Electronmicrograph showing β cell of islet of Langerhans in pancreas of buffalo. x 2000
N-Nucleus
Ib-Inclusion body
Blue arrow-membrane bound halo, around the granule.

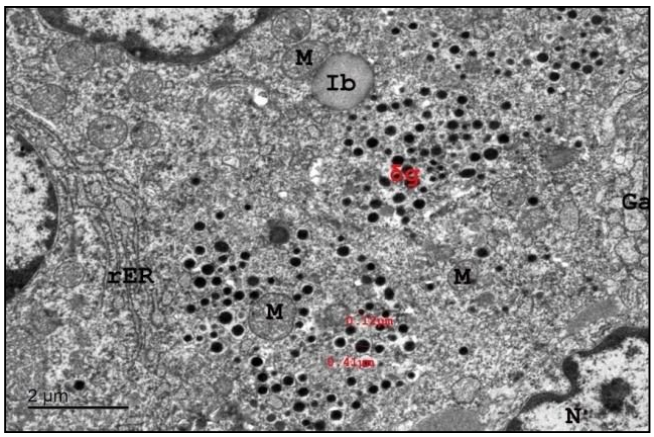


**Fig 3:** Electronmicrograph showing δ cell of islet of Langerhans in pancreas of buffalo. x 2000
M-Mitochondria
Ib-Inclusion body
N-Nucleus
rER-Rough endoplasmic reticulum
Ga-Golgi apparatus
δg-Delta granules

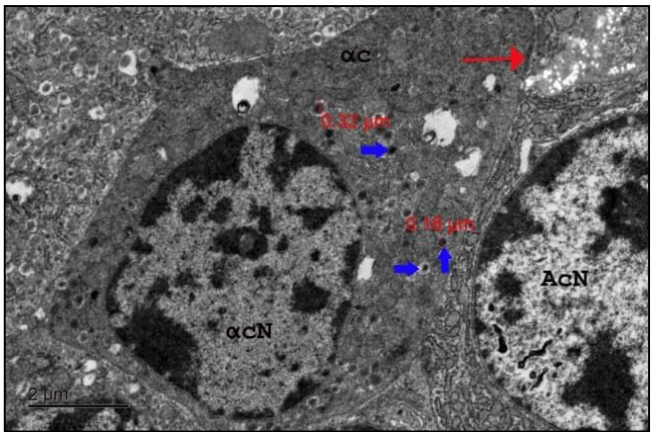


**Fig 4:** Electronmicrograph showing α cell and acinar cell in pancreas of sheep. x 2000
αc-Alpha cell
αcN-Nucleus of alpha cell
AcN-Nucleus of acinar cell
Red arrow-Intercellular junction
Blue-Alpha granules
M-Mitochondria

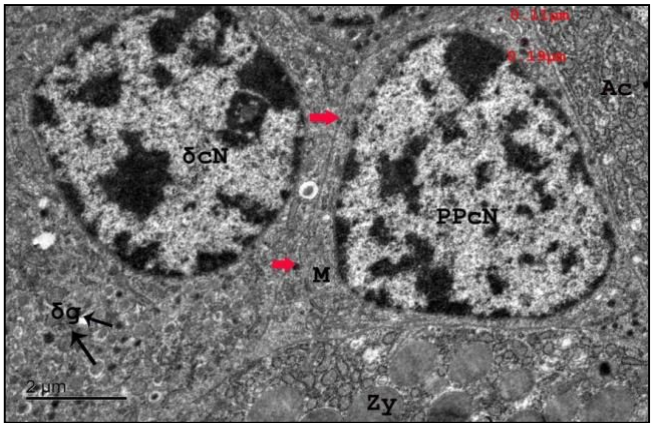


**Fig 5:** Electronmicrograph showing β cell of islet of Langerhans in pancreas of sheep. x 2000
N-Nucleus
βg-Beta granules
Blue arrow-Membrane bound 'halo' around the granule
Red arrow-Intercellular junction

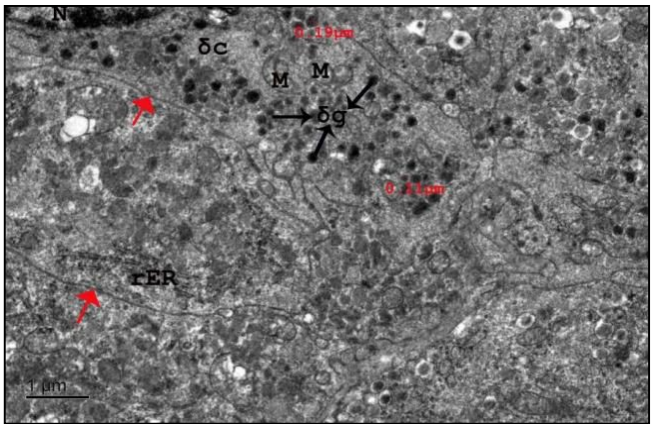


**Fig 6:** Electronmicrograph showing δ cell of islet of Langerhans in pancreas of sheep. x 2500
δc-Delta cell
N-Nucleus
M-Mitochondria
δg-Delta granules
rER-Rough endoplasmic reticulum
Red arrow-Intercellular junction

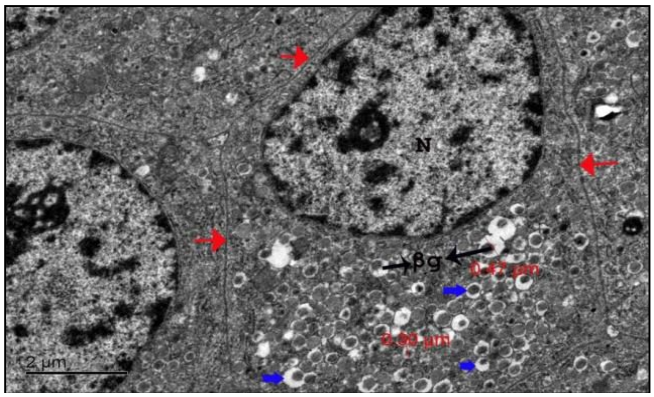


**Fig 7:** Electronmicrograph showing PP cell of islet of Langerhans in pancreas of sheep. x 2000
δcN-Nucleus of delta cell
δg-Delta granules
M-Mitochondria
PPcN-Nucleus of pancreatic polypeptide cell
Zy-Zymogen granules
Ac-Acinar cell
Red arrow-Intercellular junction

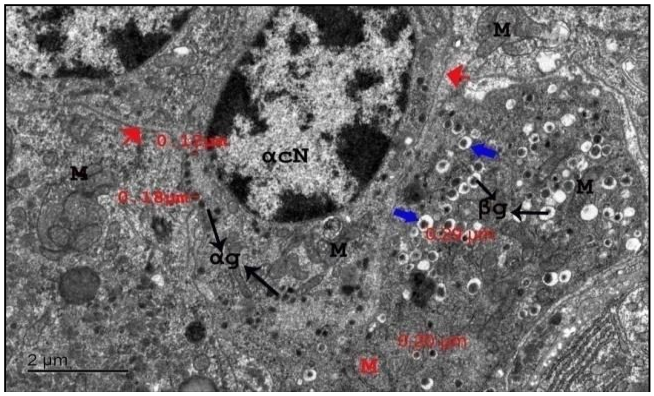


**Fig 8:** Electronmicrograph showing α and β cells of islet of Langerhans in pancreas of goat. x 2000
αcN-Nucleus of alpha cell
M-Mitochondria
αg-Alpha granules
βc-Beta cell
Red arrow-Intercellular junction
Blue arrow-membrane bound halo, around the granule

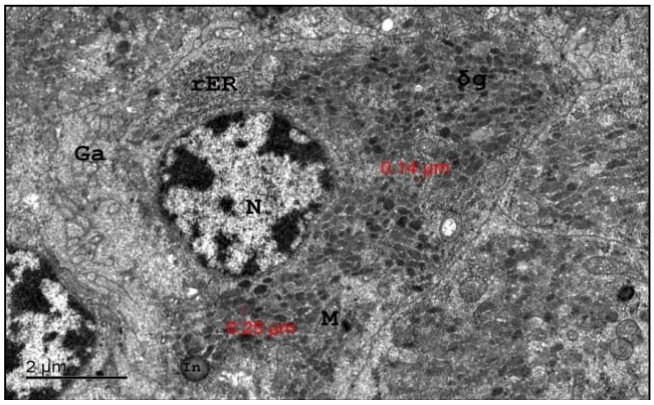


**Fig 9:** Electronmicrograph showing δ cell of islet of Langerhans in pancreas of goat. x 2000
N-Nucleus
Ga-Golgi apparatus
rER-Rough endoplasmic reticulum
Ib-Inclusion body
M-Mitochondria
δg-Delta granules

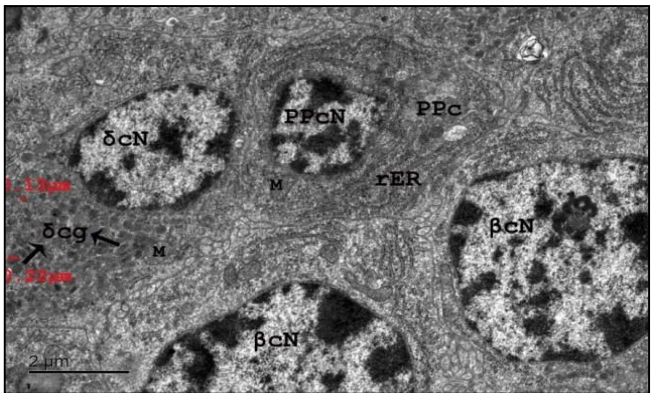


**Fig 10:** Electronmicrograph showing PP cell and δ cells in islet of Langerhans in pancreas of goat. x 2000
PPc-Pancreatic polypeptide cell
PPcN-Nucleus of pancreatic polypeptide cell
rER-Rough endoplasmic reticulum
M-Mitochondria
δcN-Nucleus of delta cell
βcN-Nucleus of beta cell

## Discussion

In the present ultrastructural investigation, the islets of Langerhans in the pancreas of buffalo, sheep, and goat exhibited four distinct endocrine cell types i.e α, β, δ, and PP-cells consistent with the classifications reported by Sato *et al.* (1966) [15], Weir and Like (1980) [17], and Hafez and Zaghloul (2017). The α-cells were consistently located at the periphery of the islets in all three species. In buffalo, α-cells were characterized by densely packed, electron-dense secretory granules surrounded by a narrow and distinct halo, suggesting intense glucagon synthesis. In sheep, α-cells contained fewer, moderately electron-dense granules with indistinct halos, whereas in goats, the granules were smaller, sparsely distributed, and lacked a halo. These interspecies variations are comparable to the findings of Lacy (1957) [6] and Lukinius *et al.* (1992) [9], who reported that α-cell granule morphology varies among species in density and halo prominence. The presence of elongated mitochondria and abundant rER in buffalo α-cells indicates greater metabolic and secretory activity, similar to the observations of Weir and Like (1980) [17] in bovine pancreas.

The β-cells represented the predominant population in all three species and were concentrated in the central regions of the islets. In buffalo, β-cells exhibited large, oval to spherical secretory granules with well-defined halos and variable electron density, while in sheep and goats, the granules were less electron-dense and slightly smaller. These findings are in agreement with Lacy (1957) [6], who described rod or bar-shaped β-granules in dogs, and Pelletier (1977) [13], who noted crystalline cores in human β-granules. The well-developed Golgi complex and numerous mitochondria observed in buffalo and sheep β-cells denote a high level of insulin synthesis and secretion, corroborating the reports of Sato *et al.* (1966) [15] and Machino (1973) [10].

The δ-cells, though fewer, were located mainly at the islet periphery in all three species. They contained small to moderately electron-dense granules surrounded by a distinct halo in buffalo, while in sheep and goats, the granules were diamond to urn-shaped with moderate electron density. These morphological patterns are comparable to those reported by Legg (1967) [8] in cats and Forssmann (1976) [4] in horses. The presence of elongated cytoplasmic processes

in δ-cells of sheep and goats suggests a paracrine modulatory function, as described by Baskin *et al.* (1984) [2]. The PP-cells were sparse and situated at the periphery of the islets in all species, containing small, moderately electron-dense granules without distinct halos, which agrees with observations by Weir and Like (1980) [17] and Vantyghem *et al.* (1996) [16]. Overall, buffalo exhibited larger, denser secretory granules and richer organelle organization compared to sheep and goats, indicating relatively higher endocrine activity. These comparative ultrastructural findings reveal significant interspecies differences in granule morphology, density, and cytoplasmic organization, reflecting functional adaptations in endocrine pancreatic physiology among domestic ruminants.

## Conclusion

In conclusion, the pancreatic islets of buffalo, sheep, and goat exhibited distinct ultrastructural variations among α, β, δ, and PP cells. Buffalo showed larger, denser granules and richer organelle organization, indicating higher endocrine activity, whereas sheep and goats displayed relatively smaller and less dense granules. These interspecies differences reflect adaptive variations in hormonal synthesis and secretory efficiency among domestic ruminants.

## Acknowledgments

I express my sincere gratitude to Dr. Chandra Sekhar, Professor and Head, Department of Neuropathology, and to Dr. Reshmi and Mr. Ramesh for their invaluable support and for providing the necessary facilities for Electron Microscopy at NIMHANS, Bangalore. Their guidance and cooperation were instrumental in the successful completion of this research work.

## References

1. Bancroft JD, Gamble M. Theory and practice of histological techniques. 6th ed. Churchill Livingstone Elsevier; 2008. p. 248-250.
2. Baskin DG, Gorray KC, Fujimoto WY. Immunocytochemical identification of cells containing insulin, glucagon, somatostatin, and pancreatic polypeptide in the islets of Langerhans of the guinea pig pancreas with light and electron microscopy. The Anatomical Record. 1984;208:567-578.
3. Caramia F, Munger BL, Lacy PE. The ultrastructural basis for the identification of cell types in the pancreatic islets of the guinea pig. Zeitschrift für Zellforschung. 1965;67:533-546.
4. Forssmann A. The ultrastructure of the cell types in the endocrine pancreas of the horse. Cell and Tissue Research. 1976;161(2):179-195.
5. Hafez S, Zaghloul D. Light and electron microscopy of the pancreas of the Egyptian one-humped camel (*Camelus dromedarius*). European Journal of Anatomy. 2017;21(1):37-45.
6. Lacy PE. Electron microscopic identification of different cell types in the islets of Langerhans of the guinea pig, rat, rabbit, and dog. The Anatomical Record. 1957;128:255-268.
7. Lacy PE. Electron microscopy of the beta cell of the pancreas. American Journal of Medicine. 1961;31:851-859.
8. Legg PG. The fine structure and innervation of the beta and delta cells in the islet of Langerhans of the cat. Zeitschrift für Zellforschung. 1967;80:307-321.
9. Lukinius A, Ericsson JL, Grimelius L, Korsgren O. Ultrastructural studies of the ontogeny of fetal human and porcine endocrine pancreas, with special reference to colocalization of the four major islet hormones. Developmental Biology. 1992;153:376-385.
10. Machino M. The substructure of crystalloids in secretory granules of dog pancreatic islet B cell. The Anatomical Record. 1973;177:39-48.
11. Masaad GAM. A comparative morphological study on the pancreas of the dromedary (*Camelus dromedarius*) and the donkey (*Equus asinus*). M.V.Sc Thesis, B.V.M. University of Khartoum; 2007.
12. Meshram B, Dalvi RS, Nagmalleshwari Y, Kamble M. Age-related histomorphological and transmission electron microscopic studies of the pancreatic islets in goats. Journal of Agriculture and Veterinary Science. 2015;8(11):37-45.
13. Pelletier G. Identification of four cell types in the human endocrine pancreas by immunoelectron microscopy. Diabetes. 1977;26(8):749-756.
14. Pfeifer CR, Shomorony A, Aronova MA, Zhang G, Cai T, Xu H, Notkins AL, Leapman RD. Quantitative analysis of mouse pancreatic islet architecture by serial block-face SEM. Journal of Structural Biology. 2015;189(1):44-52.
15. Sato T, Herman L, Fitzgerald PJ. The comparative ultrastructure of the pancreatic islet of Langerhans. General and Comparative Endocrinology. 1966;7:132-157.
16. Vantyghem MC, Conte JK, Pattou F, Gevaert MH, Hober C, Defossez A, Mazzuca M, Beauvillain JC. Immunohistochemical and ultrastructural study of adult porcine endocrine pancreas during the different steps of islet isolation. Histochemistry and Cell Biology. 1996;106(5):511-519.
17. Weir SB, Like AA. A dual population of islets of Langerhans in bovine pancreas. Cell and Tissue Research. 1980;206(1):157-170.