International Journal of Advanced Biochemistry Research

ISSN Print: 2617-4693
ISSN Online: 2617-4707
IJABR 2025; SP-9(3): 05-09
www.biochemjournal.com
Received: 04-12-2024
Accepted: 10-01-2025

Aruna Panwar
Department of Veterinary Anatomy, College of Veterinary and Animal Science, Rajasthan University of Veterinary and Animal Sciences, Bikaner, Rajasthan, India

Pankaj Kumar Thanvi
Department of Veterinary Anatomy, College of Veterinary and Animal Science, Rajasthan University of Veterinary and Animal Sciences, Bikaner, Rajasthan, India

Ashok Dangi
Department of Veterinary Anatomy, College of Veterinary and Animal Science, Rajasthan University of Veterinary and Animal Sciences, Bikaner, Rajasthan, India

Devendra Singh
Department of Veterinary Anatomy, College of Veterinary and Animal Science, Rajasthan University of Veterinary and Animal Sciences, Bikaner, Rajasthan, India

Raj Kumar Siyag
Department of Veterinary Anatomy, College of Veterinary and Animal Science, Rajasthan University of Veterinary and Animal Sciences, Bikaner, Rajasthan, India

Nitin Sharma
Department of Veterinary Anatomy, College of Veterinary and Animal Science, Rajasthan University of Veterinary and Animal Sciences, Bikaner, Rajasthan, India

Corresponding Author:
Aruna Panwar
Department of Veterinary Anatomy, College of Veterinary and Animal Science, Rajasthan University of Veterinary and Animal Sciences, Bikaner, Rajasthan, India

Histochemical studies of the liver of dromedary camel (*Camelus dromedarius*)

Aruna Panwar, Pankaj Kumar Thanvi, Ashok Dangi, Devendra Singh, Raj Kumar Siyag and Nitin Sharma

DOI: https://www.doi.org/10.33545/26174693.2025.v9.i3Sa.3881

Abstract
The present investigation was conducted on the livers procured from ten recently died adult camels of both genders. The liver was the largest gland of the animal body which had both external and internal secretion. The capsular area of the liver showed the strong reaction for the presence of glycogen showed the role in glucose metabolism. The hepatic lobule and sinusoidsal space observed with the scatterd granules of glycogen. The central vein and interlobular septum showed weak Mc manus PAS reaction for glycogen. Kupffer cells cytoplasm showed the strong positive reaction for Mc'manus PAS. The area around the central vein and portal triad showed positive reaction for lipid in landing's method. The hepatocytes area was observed with the lipid particles. The mucosubstances were clearly seen in the hepatic artery as well as in bile ductules. The biliary glands showed the intense positive reaction in PAS-Alcian blue pH 2.5 for mucosubstances.

Keywords: Central vein, hepatocyte and glycogen

Introduction

The Indian camel are single humped (*Camelus dromedarius*) and as a rule is less heavily built, longer in the hind part with soft coat and comparatively thin body. The camel is an even-toed ungulate (artiodactyla) that traverses long distances and has a great capability of tolerating adverse environmental conditions such as high temperature, non-availability of water and starvation for long period.

This is being probably made possible by adaptations exhibited by camel like its size and shape, colour, tolerance of high temperature and tissue dehydration, reduction in metabolic rate etc. (Wilson, 1989) [23].

Liver has both external and internal secretions, which are formed in the hepatic cells also called as hepatocytes. Its external secretion, the bile, is collected after passing through the bile capillaries by the bile ducts, which join like the twigs and branches of a tree to form two large ducts that unite to form the hepatic duct (Klein, (2021) [7] and Reece (2009) [17]. The hepatic duct joins the pancreatic duct before entering the duodenum. Bile flows constantly and drains into the duodenum as camel lacks gall bladder. Primary function of the liver is excretion of bilirubin, cholesterol, hormones and drugs. The endocrine secretion of the liver hepatocytes involves synthesis of numerous plasma proteins, including albumin and the blood-clotting factors prothrombin and fibrinogen.

Histochemical studies of the camel liver involved analyzing tissue sections for specific chemical components to understand the liver's structure and functions. The liver plays important role in the glucose metabolism. It also stores fats, various vitamins, and carbohydrates as glycogen. When the cells of the body need glucose, glycogen that is stored in the liver is converted back into glucose and released into the blood stream. The products of digestion, which are conveyed in the blood stream after absorption, are presented to the hepatic cells before entering the general circulation.

The data of the present study will be valuable for understanding not just the biology of camels but also broader principles of liver functioning and unique adaptation and physiological mechanism for their survival in harsh environment.

Materials and Methods

The present study was conducted on liver of ten recently died camel which were free from any pathological condition of liver were procured from Veterinary Clinical Complex, RAJUVAS, Bikaner and investigated in the Department of Veterinary Anatomy, College of Veterinary and Animal Science, Bikaner. The collected samples were used for histochemical study.

Histochemical studies

For this small pieces (2-3 mm size) of representative areas of livers were collected from identical sites and fixed in 10% neutral buffered formalin or Bouin's fluid for 24-72 hours and 18-24 hours respectively followed by overnight washing in running tap water, dehydration in ascending order of alcohol (50%, 70%, 90% and then Absolute Alcohol-I, II & III), clearing in chloroform and finally embedding in paraffin wax. Paraffin blocks were prepared, numbered and stored at 4 °C. Five to six micron thick sections were cut by using semi-automatic microtome then sections were mounted of the on albumenized slides and drying of section and then staining were done. Periodic acid-Schiff (PAS) reaction for glycogen (Singh and Sulochana (1997) [21], Landing's method for lipids and PAS Alcian Blue reaction for mucous substances were carried out Luna (1968) [10].

Results and Discussion

Periodic acid-Schiff (PAS) reaction for glycogen

In present study the capsule of the liver showed moderate PAS positive reaction (Fig. 4) which was in partial agreement with the findings of Dhoolapa *et al*. (2003) [3] in donkey showed strong PAS positive reaction. Modekar *et al*. (2003) [13] in goat and Madhu *et al*. (2022) [11] in nilgai found weak PAS positive reaction at the capsular region. The Interlobular connective tissue septum showed the presence of glycogen in moderate amount (Figs.1 and 3) which was not reported by the Pareek (2000) [14] in *Magra* sheep and Madhu *et al*. (2022) [11] in nilgai. Weak PAS positive reaction was seen at the portal triad (Fig. 1) also observed by the Sethi *et al*. (2021) [18] in Bakerwali goat.

In hepatic lobule all three zones showed different reaction. From zone 1 near the interlobular connective tissue septum there was intense reaction for the glycogen. Near central vein at zone 3 there was moderate reaction (Figs. 1 and 3). The zone 2 showed the weak PAS positive reaction. These observations were in close harmony with the findings of the Miraglia *et al.* (1975) [12] in monkey, Modekar *et al*. (2003) [13] and Sethi *et al*. (2021) [18] in goat.

Hepatocytes showed the intense PAS positive reaction throughout the parenchyma (Fig. 2). This was in close agreement with the reports of Aziz (1984) [1] in sheep, Modekar *et al*. (2003) [13], Bamaniya (2013) [2] in goat, Siddig *et al*. (2015) [19] in camel, Rashad *et al*. (2017) [16] in buffalo Singh (2019) [20] in pig and Sethi *et al*. (2021) [18] in Bakerwali goat.

In present study the macrophages Kupffer cell showed intense PAS positive reaction (Fig. 2) also noticed by Ghumico and Miller (1981) [5] in mammals, Rashad *et al.* (2017) [16] in water buffalo. However, Aziz (1984) [1] in sheep found moderate reaction in Kupffer cells.

Sinusoidal space and endothelial cells both showed the lamina of glycogen (Fig. 2) also illustrated by Kalita *et al.* (2019) [6] in pig and Eroschenko (2008) [4] in ruminants.

Landing's method for lipids

In present study the capsule of liver showed the weak reaction for lipid also observed by Siddig *et al*. (2015) [19] in camel, Rashad *et al*. (2017) [16] in buffalo and Sethi *et al*. (2021) [18] in Bakerwali goat.

The portal area of the tissue had moderate reaction for the lipid presence. The lipid droplets and granular cytoplasm was seen throughout the liver parenchyma (Fig. 5) which was also seen by the Thakur (2020) [22] in buffalo and Sethi *et al*. (2021) [18] in Bakerwali goat.

The cytoplasm of hepatocyte showed strong reaction for the presence of lipid in Landing's method (Fig. 4). Around the central veins the strong reaction was seen (Fig. 8). Zone 3 showed intense reaction and mild to moderate reaction was visible in the zone 1 and 2 (Fig. 8) also favoured the observation of the Siddig *et al*. (2015) [19] in camel and Sethi *et al.* (2021) [18] in Bakerwali goat.

Lipid droplets were present throughout the liver lobule in various sizes (Fig. 8) which contribute to energy storage and metabolism. Numerous cytoplasmic vesicles were seen at sinusoidal space of the hepatocytes (Fig. 8). At inter lobular septum the reaction was strong for the lipid (Fig. 8) also observed by Siddig *et al*. (2015) [19] in camel, Rashad *et al*. (2017) [16] in buffalo and Sethi *et al*. (2021) [18] in Bakerwali goat.

PAS Alcian Blue reaction for mucous substances

In present study the liver of the camel showed the moderate reaction for presence of mucopolysaccharide at the capsular region (Fig. 5) also reported by the Sethi *et al*. (2015) [18] in the Bakerwali goat. The biliary glands showed intense positive reaction near the hepatic duct (Fig. 7). At central vein area and hepatocytes there were presence of mucosubstances (Fig. 5) which was in partial harmony with the observation of Modekar *et al*. (2003) [13] in goat seen the moderate reaction.

At portal triad region the reaction for mucosubstances was strong (Fig. 6). Bile duct and hepatic artery showed the moderate reaction (Figs. 5 and 6). The tunica intima and tunica adventitia showed the strong reaction however, tunica media of hepatic artery showed weak reaction for mucosubstances at PAS-Alcian Blue pH 2.5 (Fig. 6). The bile ductule inner epithelium showed positive reaction in PAS-Alcian blue pH 2.5 (Fig. 6).

The hilus at the visceral surface of the liver showed the moderate reaction (Fig. 7). The inner lining of the hepatic artery showed the intense positive reaction for the PAS-Alcian blue stain at pH 2.5 (Fig. 6). Around the central vein and trabeculae there were moderate reactions for the mucosubstances (Fig. 5). Modekar *et al*. (2003) [13] and Sethi *et al*. (2021) [18] in goat liver observed mild positive PAS Alcian Blue pH 2.5 reactions around central vein.

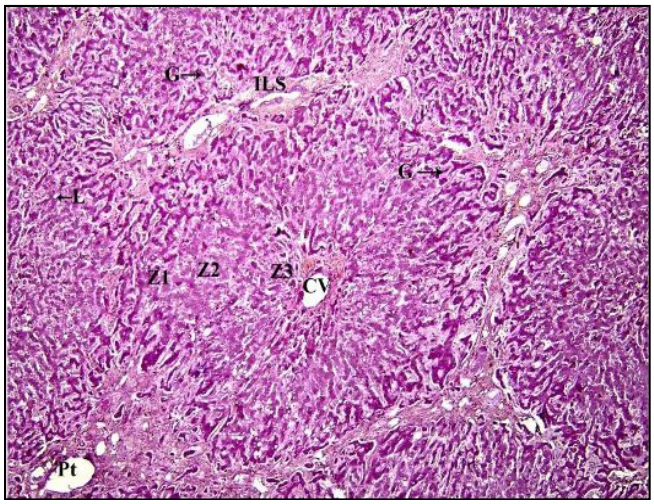

Fig 1: Photomicrograph showing the Glycogen in different zones of Hepatic lobule. G-Glycogen, CV-Central vein, L-lobule, ILS-Interlobular septum and Z-Zone.
(McManus PAS for glycogen, 100X)

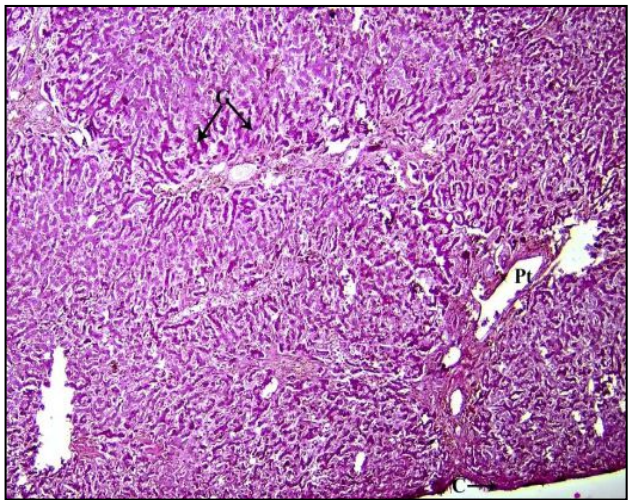

Fig 4: Photomicrograph showing the PAS positive reaction at the capsule and hepatic lobule of liver. Pt-Portal triad, G-Glycogen and C-Capsule.
(McManus PAS for glycogen, 100X)

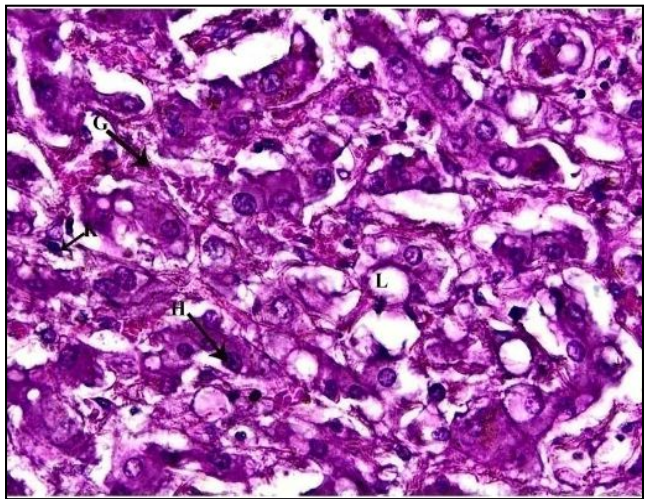

Fig 2: Photomicrograph showing the PAS positive reaction at the parenchyma of the liver. H-Hepatocyte, K-Kupffer's cell, G-Glycogen and L-Lipid droplets.
(McManus PAS for glycogen, 400X)

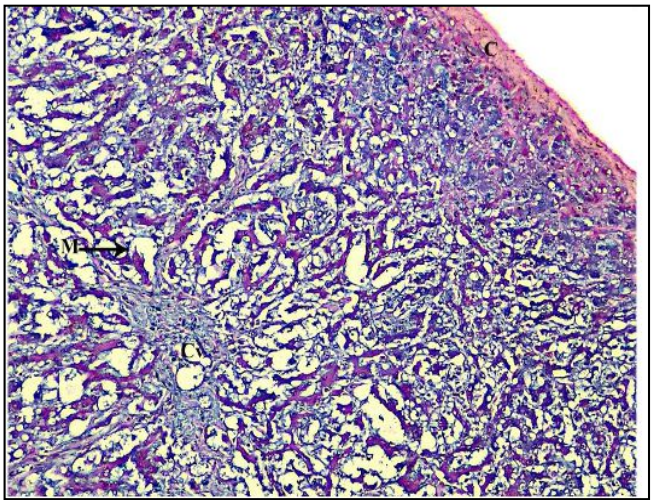

Fig. 5: Photomicrograph showing the positive reaction in hepatic lobule of liver. C-Capsule, M-Mucosubstances and CV-Central vein.
(PAS-Alcian blue for Mucosubstances pH 2.5, 100X)

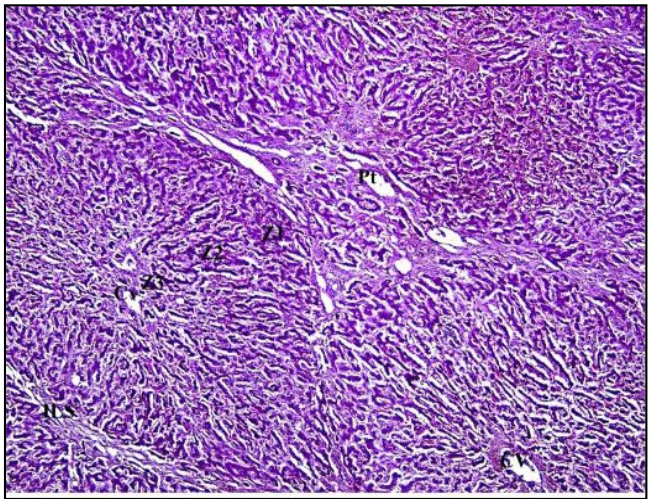

Fig 3: Photomicrograph showing the intense PAS positive reaction near the hilus region of liver. Cv-Central vein, Pt-Portal triad, ILS-Inter lobular septum and Z-Zone.
(McManus PAS for glycogen, 100X)

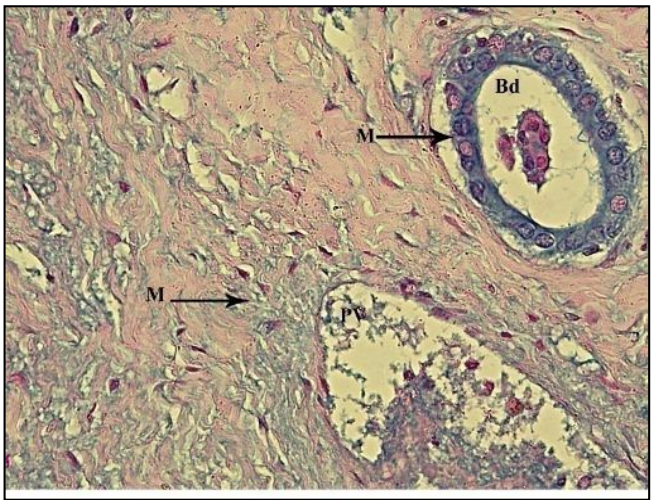

Fig 6: Photomicrograph showing the positive reaction for mucosubstances at the portal triad. Pv-Portal vein, M-Mucosubstances and Bd-Bile ductule.
(PAS-Alcian blue for Mucosubstances pH 2.5, 400X)

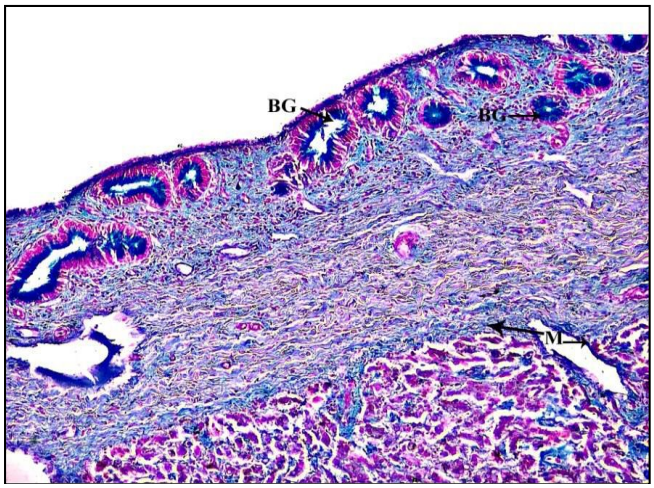

Fig 7: Photomicrograph showing the positive reaction for mucosubstances in Biliary glands. BG-Biliary glands and M-Mucosubstances.
(PAS-Alcian blue for Mucosubstances pH 2.5, 100X)

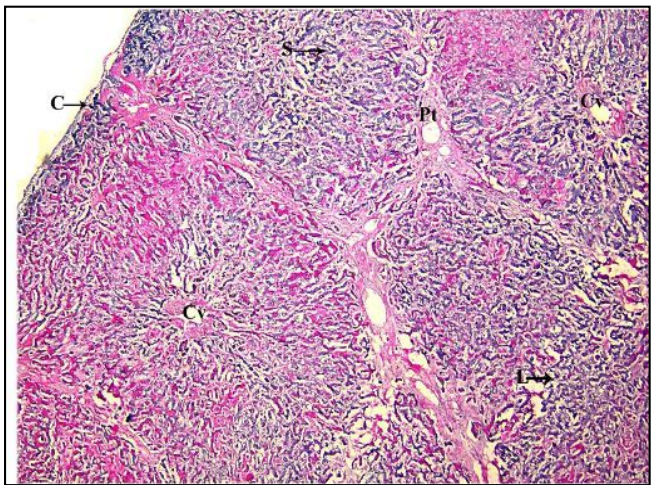

Fig 8: Photomicrograph showing the positive reaction for lipid in the stroma and parenchyma of liver. L-Lipid, Pt-Portal triad, S-Sinusoids and Cv-Central vein.
(Landing's method for lipid, 40X)

Conclusion

The histochemical study of the camel liver using PAS, Landing's method, and PAS-Alcian Blue staining revealed significant findings regarding the distribution of glycogen, lipids, and mucopolysaccharides. The liver capsule and interlobular connective tissue displayed moderate PAS-positive reactions for glycogen, with hepatocytes showing strong reactions, indicating their role in glycogen storage. Kupffer cells exhibited intense PAS positivity, reflecting their involvement in glycogen metabolism. Lipid droplets were observed throughout the liver, particularly around central veins, emphasizing their contribution to energy storage. The study also highlighted moderate mucopolysaccharide reactions in various liver structures, such as the biliary glands and portal triads, supporting their functional role in maintaining liver physiology. These findings provide valuable insights into the biochemical composition and functional architecture of the camel liver.

References

1. Aziz SH. Gross, histomorphological and histochemical studies on liver of sheep. M.V.Sc. thesis, Punjab Agricultural University, Ludhiana, India; 1984.
2. Bamaniya MK. Gross and histological studies on the liver of Marwari goat (*Capra hircus*). M.V.Sc. thesis, Rajasthan University of Veterinary and Animal Sciences, Bikaner, India; 2013.
3. Dhoolappa M, Pawar A, Ramkrishna V. Macro and microanatomy of liver and pancreas in Indian donkey. XVIII Annual Convention of Indian Association of Veterinary Anatomists and National Symposium on 'Recent Advances in Veterinary Anatomy and Their Applications in the Field of Animal Health, Production and Biotechnology'; 2003. p. 97.
4. Eroschenko VP, Di Fiore MS. DiFiore's atlas of histology with functional correlations. Lippincott Williams and Wilkins. 11th edition; 2008. pp. 313-323.
5. Gumucio JJ, Miller DL. Functional implications of liver cell heterogeneity. Gastroenterology. 1981;80:2.
6. Kalita P, Doley P, Choudhary O, Das H, Debroy S. Liver and pancreas of Mizo local pig (Zovawk): A histomorphological and histochemical analysis. International Journal of Livestock Research. 2019;9:150-156.
7. Klein TBG. Cunningham's textbook of veterinary physiology. 6th ed. Elsevier Health Sciences; 2021. pp. 353-356.
8. Konig HE, Liebich HG. Veterinary anatomy of domestic mammals. 7th ed; 2020.
9. Kumar BML. Histology, histochemistry, and ultrastructure of heart, liver, and pancreas in pigs (*Sus scrofa domesticus*). Ph.D. thesis. Karnataka Veterinary Animal and Fisheries Sciences University, Bidar, India; 2018.
10. Luna LG. Manual of histological staining methods of armed force institute of pathology. 3rd ed. McGraw-Hill Book Company, New York; 1968. p. 87-88, 94-95.
11. Madhu D, Prasad RV, Jamuna KV, Sathyanarayan K, Nagaraj CS, Shridhar NB. Histological structure of liver in nilgai (*Boselaphus tragocamelus*). International Journal of Chemical Studies. 2022;11(1):51-54.
12. Miraglia T, Siqueira LA, Gorini D, Pinto G. Hisochemical data on the liver of marmoset (monkey) (*Callithrix jacchus*). Acta Anat. 1975;91:57-70.
13. Modekar SS, Bhosle NS, Mamde CS. Morphological study of liver in Osmanabadi goat (*Capra hircus*). Indian Journal of Veterinary Anatomy. 2003;15(1/2):65-67.
14. Pareek P. Gross and histological studies of the liver in Magra sheep (*Ovis aries*). M.V.Sc. thesis, College of Veterinary and Animal Science, Rajasthan Agricultural University, Bikaner, India; 2000. p. 1-78.
15. Prunescu CC, Prunescu P, Krasińska M, Krasiński ZA. Liver histological structure in adult European bison (*Bison bonasus*). Folia Morphol. 2002;61(3):137-142.
16. Rashad E, El-Haback HA, Abd Rabou MI, Hussein S, Khalifa EF. Gross anatomy and morphology of Egyptian water buffalo's liver (*Bubalus bubalis*) with reference to some histochemical and immunohistochemical evaluation. Research Journal of Pharmaceutical, Biological and Chemical Sciences. 2017;8(3):45-60.
17. Reece WO. Functional anatomy and physiology of domestic animals. 4th ed; 2009. p. 390-392.
18. Sethi L, Suri S, Sarma K, Sasan JS. Histomorphology and histochemistry of liver of adult Bakerwali and non-descript goats of Jammu, India. Journal of Animal

Research. 2021;11(3):487-495.
19. Siddig RS, Abdalla AB, Ismail HI. Some histochemical and morphometric observations on the liver of the dromedary camel (*Camelus dromedarius*). Global Journal of Animal Scientific Research. 2015;3(2):503-511.
20. Singh K. Histomorphochemical study on hepatic architecture of pig. M.V.Sc. thesis, Guru Angad Dev Veterinary and Animal Sciences University, Ludhiana, India; 2019.
21. Singh UB, Sulochana SA. Handbook of histological and histochemical technique. Premier Publishing House, Hyderabad; 1997. p. 8-57.
22. Thakur PN. Histochemical studies of liver in buffalo (*Bubalus bubalis*). Buffalo Bulletin. 2020;39(2):139-144.
23. Wilson RT. The one-humped camel in the world. Options Méditerranéennes. Serie Seminaires; 1989. p. 15-17.