International Journal of Advanced Biochemistry Research

ISSN Print: 2617-4693
ISSN Online: 2617-4707
IJABR 2024; SP-8(3): 672-679
www.biochemjournal.com
Received: 14-12-2023
Accepted: 16-01-2024

Kolangath SM
Wildlife Research & Training Centre, Gorewada Maharashtra Animal & Fishery Sciences University, Nagpur, Maharashtra, India

Gawande AP
Wildlife Research & Training Centre, Gorewada Maharashtra Animal & Fishery Sciences University, Nagpur, Maharashtra, India

Dhoot VM
Wildlife Research & Training Centre, Gorewada Maharashtra Animal & Fishery Sciences University, Nagpur, Maharashtra, India

Bhadane BK
Wildlife Research & Training Centre, Gorewada Maharashtra Animal & Fishery Sciences University, Nagpur, Maharashtra, India

Pawshe MD
Wildlife Research & Training Centre, Gorewada Maharashtra Animal & Fishery Sciences University, Nagpur, Maharashtra, India

Kaore MP
Nagpur Veterinary College, Nagpur, Maharashtra, India

Kolangath RM
St. Francis deSales College, Seminary Hills, Nagpur, Maharashtra, India

Upadhye SV
Wildlife Research & Training Centre, Gorewada Maharashtra Animal & Fishery Sciences University, Nagpur, Maharashtra, India

Corresponding Author:
Upadhye SV
Wildlife Research & Training Centre, Gorewada Maharashtra Animal & Fishery Sciences University, Nagpur, Maharashtra, India

Molecular evidence of Elephant Endotheliotropic Herpes Virus (EEHV) from Maharashtra, India

Kolangath SM, Gawande AP, Dhoot VM, Bhadane BK, Pawshe MD, Kaore MP, Kolangath RM, and Upadhye SV

DOI: https://doi.org/10.33545/26174693.2024.v8.i3Si.856

Abstract
Background: Elephant Endotheliotropic Herpes Virus (EEHV) is a significant disease of elephants and has been reported in captive and free-ranging elephants. The disease considerably impacts conservation efforts due to high mortality rates in juvenile elephants. The case presentation discusses the investigation of elephant calf mortality due to EEHV supplemented with molecular, histopathological, and phylogenetic investigations.
Case-presentation: Arjun, a five-year-old Asian elephant (*Elephas maximus),* was found dead after a brief illness. A post-mortem examination was performed, and samples were collected for histopathology and molecular diagnosis. PCR and sequencing confirmed EEHV 1A. The sequence was similar to sequences of EEHV from Assam, India, and Switzerland. The amino acid alignment revealed four substitutions in the U38 protein, due to which the distinct virus was placed separately at the base of the phylogenetic tree.
Conclusion: EEHV is a lethal infection in Asian elephants. Molecular techniques confirmed the classical gross and histopathological lesions**.** EEHV-1A, confirmed in this case, is considered virulent circulating field strain and sequencing efforts are a must to monitor the virus. Considering the dynamic nature of the virus, the herding nature of the species, its impact on juvenile calves, and the lifelong shedding of the virus from adult carriers, it is required to keenly investigate the prevalence and impact of the disease in free-range and captive elephants.

Keywords: Elephant endotheliotropic herpes virus, EEHV, elephants, *Elephas maximus*

Introduction

Elephant Endotheliotropic Herpes Virus (EEHV) is a significant disease of elephants and has been reported in captive and wild elephants worldwide. The disease appears to be lethal in Asian elephants, while in the African counterparts, the disease manifestations are mild [1]. A virus of the Proboscivirus genus, Betaherpesvirinae subfamily, Herpesviridae family and Herpesvirales order causes the disease. There are over 100 known herpes viruses, of which EEHV IA & EEHV IB have contributed to most fatalities in Asian elephants [2, 3]. There are seven known serotypes of EEHV circulating in the Asian elephants. The disease is called 'calf killer' since young elephants aged 0 to 8 years are more susceptible to the infection, and many infected cases are fatal. The virus is shed in the secretions of the infected elephants, including the trunk secretions. The transmission of the virus is majorly due to secretions of the trunk. However, herds reporting deaths due to EEHV fail to exhibit the virus by molecular screening. There is no evidence of vertical transmission of the virus. The viremia in affected cases is inconsistent, so diagnosing the disease is challenging. Recent studies have pointed out the spike in viremia before the onset of clinical disease in juvenile elephants. Between 2006 and 2018, fifty-eight cases of EEHV were reported in Thailand; EEHV1 contributed to 76% of infections, followed by EEHV4, contributing to 20% of infections. The overall mortality rate was 69% [4, 5]. There are treatment protocols in the clinical management of EEHV using antivirals like famciclovir and acyclovir with feeble success. The disease is prevalent in captive and wild elephants and does not show predilection based on sex. The disease has been reported in more than ten Southeast Asian countries where wild, captive and domestic elephant populations are predominantly based.

In many of the isolated herds in India having 5-10 elephants, only a few juveniles have survived to adulthood. Elephants are endangered in the Indian subcontinent due to illegal hunting, habitat loss, human-animal conflict, etc. EEHV can significantly impact the conservation of Asian elephants as the disease takes a heavy toll on juvenile elephants.

A 1.2-5.6% molecular prevalence has been reported in Asian elephants from Thailand; however, the seroprevalence ranging from 42.3% to 43.9% has been determined [6]. A seroprevalence of 100% was reported in captive elephants from the USA [7, 8]. Despite identifying the virus in 1971, very scarce information on the mode of transmission, incubation period, predisposing factors etc., is available. There have been a few reports of EEHV in Asian Elephants in India [9]. However, few detailed investigations have been undertaken based on molecular assays and phylogeny. The current case report deals with the post-mortem examination and molecular confirmation of EEHV in an Asian Elephant.

Case History

Arjun, a five-year-old Asian Elephant (*Elephas maximus*), was noticed with lethargy, fever, dullness and diarrhoea at the Kamlapur Elephant Camp, Gadchiroli, Maharashtra, India. The animal received supportive treatment in the form of fluid and antibiotics. The animal succumbed on day 3 of the treatment. The animal exhibited lacrimation & cyanosis of the tongue on the penultimate day. The animal was unable to stand and showed signs of dullness & weakness. To investigate the cause of death, a systematic post-mortem examination was undertaken at the request of the Deputy Conservator of Forests, Forest Department, Government of Maharashtra State. The gross pathological lesions noticed during the post-mortem examination included congestion of blood vessels of the liver, focal ulceration of the tongue, generalised haemorrhage, enteritis, myocardial hypertrophy and petechial haemorrhages; heart, liver, kidney, intestine, lungs etc. Samples were preserved in formalin and processed for histopathological examination. To obtain more insights on the cause of death, molecular investigations were carried out for which DNA was isolated from the lungs, heart, tongue, liver, lymph node, intestine, and kidney and preserved at -20°C till further use. To rule out the infection, samples of all animals in the herd were collected for EEHV screening.

A Polymerase Chain Reaction (PCR) for EEHV 1,2,3,4,5,6 & 7 was carried out targeting the U38 protein of the DNA polymerase gene as described in the reference using Proflex Thermal Cycler (Mfg. Thermo Fischer, CA, USA) [10]. The amplicon was purified using QIAquick® PCR Purification Kit (Mfg. Qiagen, MD, USA) as per the manufacturer's instructions. The amplicon was sequenced using Genetic Analyser 3500 (Mfg. Thermo Fisher, CA, USA) using the Forward & Reverse primers. The obtained sequence was trimmed at ambiguous reads, and a consensus sequence was created using Mega X Software. The nBLAST tool of the NCBI (National Center for Biotechnology Information) was used to ascertain the identity of the virus. The sequence was submitted to NCBI using the BankIt tool for further retrieval. To understand the evolutionary relationship of the virus with the reported EEHV cases from India and abroad, a phylogenetic study was undertaken using Mega X Software [11]. A total of 32 sequences were retrieved from the NCBI database. Indian strains were given priority (Table 2). To maintain tree consistency, a neighbour-joining tree was constructed using Mega X software with a bootstrap value of 1000. FMDV was included as an outgroup.

Results

The Histopathological studies of the liver indicated sinusoidal congestion and degeneration of hepatocytes (Fig.1); the heart indicated extravasation of erythrocytes in the myocardial tissue (Fig.2); the tongue indicated Haemorrhagic changes in the skeletal muscle layer of the tongue accompanied by hyaline degeneration of skeletal muscles (Fig.3), while, lungs and the spleen exhibited distinct haemorrhagic changes in the tissue (Fig.4 & 5). The Lymph node exhibited apparent depletion of lymphocytes in the lymphoid follicles (Fig.6). The PCR provided an amplification of 500 bp, indicative of a positive result (Fig. 7). The sequence was found to be identical to the EEHV IA sequence reported in Asian elephants from India. (Accession No. OP222134). An accession number ON129566 was granted to the sequence by NCBI. After the confirmation of the death, it was essential to screen the rest of the herd for the infection; as a result, a thorough haemato-biochemical analysis was performed (Table 1). The platelet count was used as an early indicator of the infection. A very low platelet count was seen in the early haematology examination of elephant Basanti. Thus, screening was carried out to rule out the presence of EEHV in the foundation stock. The blood samples were screened with PCR and were found negative for all serotypes of EEHV.

On nBlast analysis, the query sequence was found to be 98.92% identical to sequences of EEHV IA reported in Asian elephants from Assam, India (Accession No. OP222134) and Switzerland (Accession No. JF692769). The phylogenetic analysis differentiated the sequences into three distinct clades. Clade I consisted of EEHV IA sequences reported from Europe and North America and sequences from India. Clade II, on the other hand, was dominated by the EEHV sequences from Thailand and Malaysia. The query sequence was distinct and placed in Clade III with sequences from Europe and North America. *Plasmodium vivax* formed a distinct outgroup (Fig. 8).

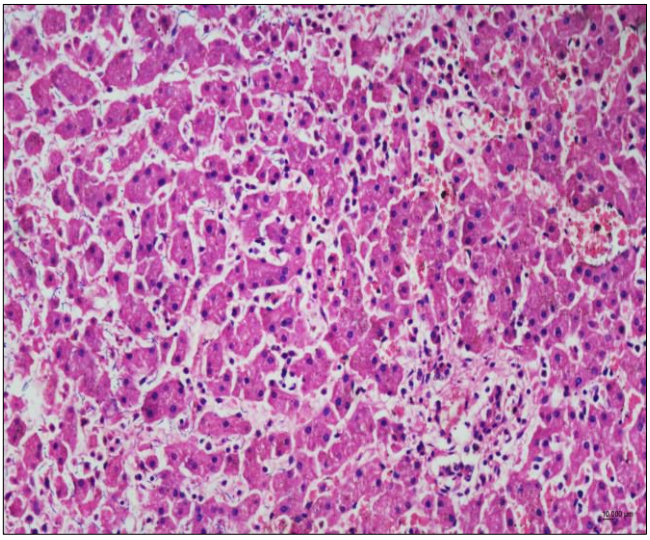

Fig 1: Liver*:* Sinusoidal congestion and degeneration of hepatocytes H&E 20x

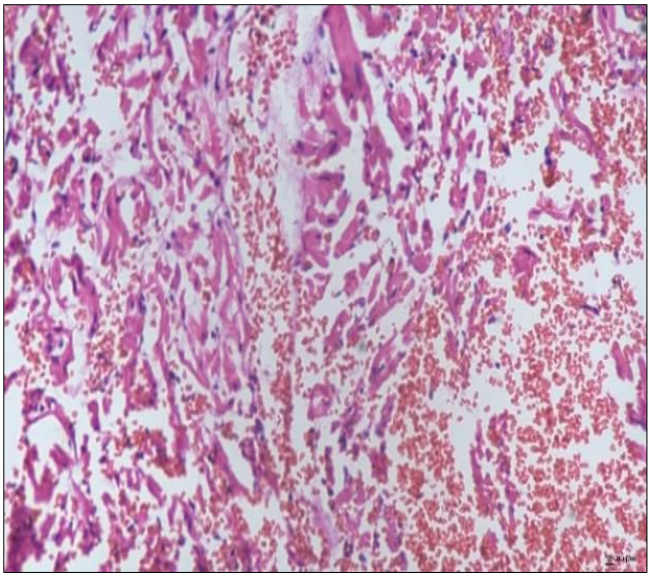

Fig 2: Heart: Extravasated erythrocytes are present in myocardium H&E 20x

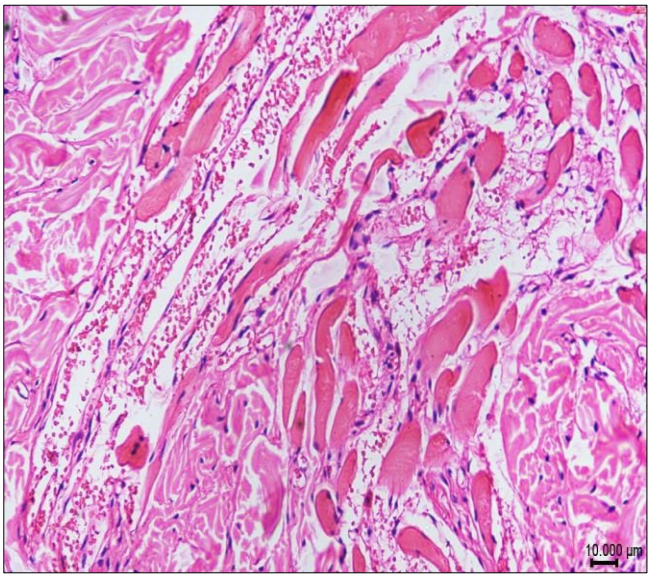

Fig 3: Tongue: Hemorrhages between the skeletal muscle layer of tongue and hyaline degeneration of skeletal muscle H & E 10×

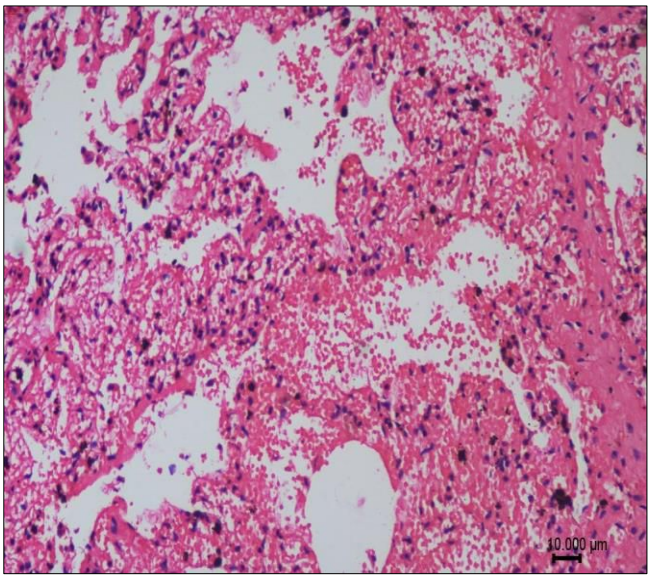

Fig 4: Lung: Hemorrhages Alveoli are filled with RBCs H&E 10×

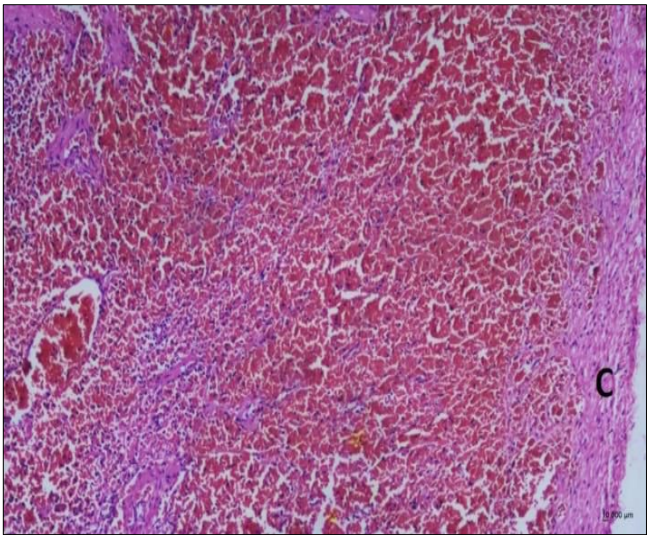

Fig 5: Spleen: Subcapsular hemorrhages in spleen H&E 20x C-Capsule

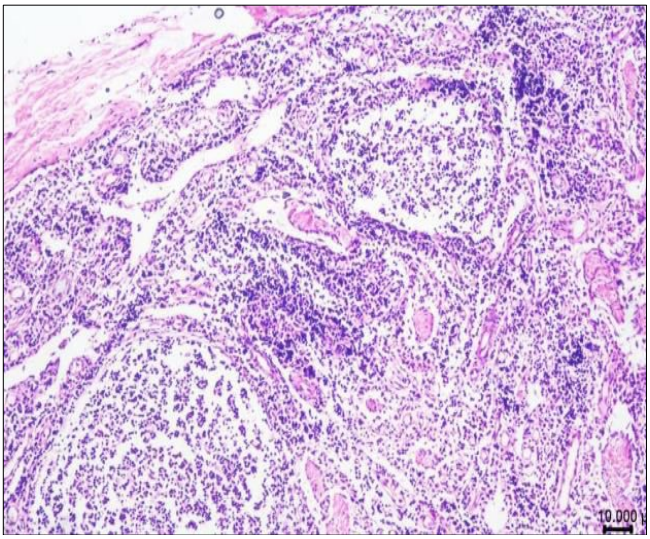

Fig 6: Lymph node: Depletion of lymphocytes in lymphoid follicles H&E 10×

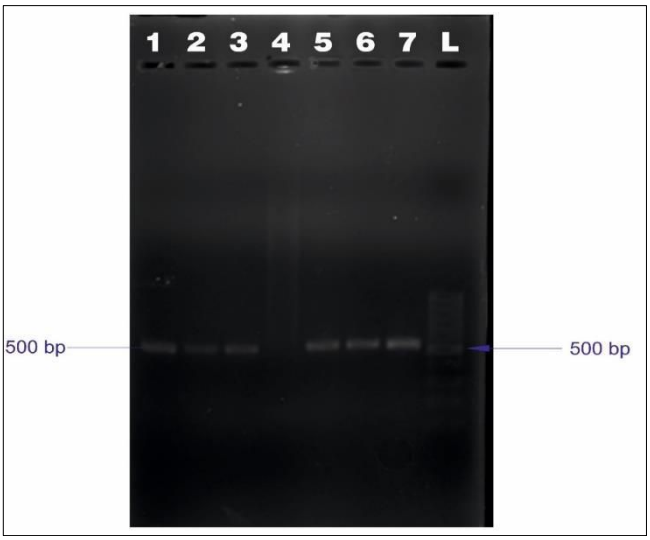

Fig 7: Agarose Gel Electrophoresis stained with ethidium bromide exhibiting an amplification of 500 bp using primers forward primer EEHV 1A and reverse primer EEHV 1B.
Lane 1: Kidney, Lane 2: Liver, Lane 3: Spleen, Lane 4: Lymph node, Lane 5: Heart, Lane 6: Lungs, Lane 7: Tongue and Lane 8: Ladder 100 bp



Fig 8: Phylogenetic analysis by Neighbour-joining method using Mega X software with a bootstrap value of 1000.

```
CLUSTAL O(1.2.4) multiple sequence alignment

KT832533    MVTTNTGRVHRFVKPHVRKSILSQLLTSWLAERKAVREKLKHCKDPLMQILLDKQQLALK    60
ON129566    MVTTNTGRVHRFVKPHVRKSILSQLLTWWLAERKAVREKLKHCKDPFMQILLDKQQLALK    60
            ************************* *****************:*************

KT832533    LTCNAVYGFTGVSKGMFPCLAIAESVTAQGRQLLAVTKQYICDRFNDWTFLTQIAPELVD    120
ON129566    LTCNAVYGFTGVSKGMFPCLAIAESVTAQGRQLLAVTKQYICDRFNDWTFLTQIAPELVD    120
            ************************************************************

KT832533    CPVDSNRFKIDVVYG-- 135
ON129566    CPVNSNIFKIDVVYGDT 137
            ***:** ********
```

Fig 9: Sequence alignment of the amino acid sequences of the EEHV U38 protein of DNA polymerase gene accession numbers KT832533 and ON129566.

Table 1: Haemato-biochemical values of the blood and sera collected from elephants of the herd.

Sr. No.	Paramater	Elephants					
		Ganesh	Basanti	Rupa	Mangala	Rani	Reference Range
1	Haemoglobin (gm/dl)	11.5	12.9	10.3	10.5	10.7	12.02 to 13.35
2	PCV (%)	35.6	36.7	31.8	31.6	31.8	34.17 to 38.02
3	MCV (fl)	121	128	121	127	125	118.97 to129.88
4	MCH (pg)	39.1	44.7	39.0	42.4	42	41.33 to 46.67
5	MCHC (gm/dl)	32.4	35.1	32.3	33.4	33.7	33.47 to 37.78
6	RDW (%)	16.7	18.6	17.0	15.9	16.0	
7	PDW (%)	9.7	8.5	7.2	9.3	8.5	
8	RBC count (mil/cmm)	2.95	2.88	2.63	2.48	2.55	2.77 to 3.06
9	Platelet count (lac/cmm)	3.87	0.99	2.92	3.52	5.41	1.22 – 3.46
10	TLC (X 1000/cmm)	16.4	13.4	15.6	12.4	21.2	12.26 to 14.35
11	Polymorphs (%)	38	44	46	49	40	37.21 to 43.56
12	Lymphocytes (%)	37	32	34	27	45	32.84 to 40.19
13	Eosinophils (%)	19	17	12	18	09	17.37 to 23.48
14	Monocytes (%)	06	07	08	06	06	0.43 to 1.64
15	Serum Urea (mg/dl)	48	42	34	30	43	15 -16
16	Serum Creatinine (mg/dl)	1.66	1.45	1.41	1.39	1.22	1.4 – 1.6
17	Serum sodium	125	127	126	123	134	
18	Serum potassium	6.9	6.7	6.2	6.2	6.0	
19	Serum SGOT (mg/dl)	122	67	58	47	56	
20	Serum SGPT (mg/dl)	70	26	19	21	18	
21	Total Serum Bilirubin	0.49	0.53	0.62	0.52	0.46	0.7-0.75
22	Direct Serum Bilirubin (mg/dl)	0.17	0.19	0.21	0.16	0.14	0.6-0.7
23	Indirect Serum Bilirubin (mg/dl)	0.32	0.34	0.41	0.36	0.32	0.1-0.15
24	Total Proteins (gm/dl)	7.83	8.59	9.06	8.77	9.01	7-9
25	Albumin (gm/dl)	3.44	2.95	2.67	3.38	3.56	2.5-3.5
26	Globulin (gm/dl)	4.39	5.64	6.39	5.39	5.45	4.5-5.5
27	Alkaline Phosphatase (IU/L)	171	94	71	101	133	240-275
28	'C' reactive protein (mg/Lit)	2.78	1.18	2.84	1.69	1.16	1-6

Table 2: Details of sequences and utilised for the phylogenetic analysis using MEGA X software

Sr. No.	Accession Number	Species	Serotype	Country	Authors
1	OP222134	*Elephas maximus*	EEHV 1A	India	Direct Submission
2	JF692769	*Elephas maximus*	EEHV 1A	Switzerland	Direct Submission
3	JF692770	*Elephas maximus*	EEHV 1A	Germany	Direct Submission
4	KT007218	*Elephas maximus*	EEHV 1A	USA	J. Virol. 88 (23), 13523-13546 (2014)
5	MN067515	*Elephas maximus*	EEHV 1A	Germany	Direct Submission
6	KT447194	*Elephas maximus*	EEHV 1A	Thailand	Direct Submission
7	KR812386	*Elephas maximus*	EEHV 1A	Thailand	Direct Submission
8	JF692758	*Elephas maximus*	EEHV 1A	Canada	Direct Submission
9	JF692752	*Elephas maximus*	EEHV 1A	USA	Direct Submission
10	MN524089	*Elephas maximus*	EEHV 1A	USA	Direct Submission
11	MN864102	*Elephas maximus*	EEHV 1A	India	Direct Submission
12	GU350749	*Elephas maximus*	EEHV 1A	USA	Direct Submission
13	KT852704	*Elephas maximus*	EEHV 1A	Thailand	Direct Submission
14	KR812387	*Elephas maximus*	EEHV 1A	Thailand	Direct Submission
15	MN366292	*Elephas maximus*	EEHV 1A	India	J. Wildl. Dis. 49 (2), 381-393 (2013)
16	MN366291	*Elephas maximus*	EEHV 1A	India	J. Wildl. Dis. 49 (2), 381-393 (2013)
17	KT596952	*Elephas maximus*	EEHV 1A	Thailand	Direct Submission
18	MF579054	*Elephas maximus*	EEHV 1A	India	Direct Submission
19	JF692773	*Elephas maximus*	EEHV 1A	United Kingdom	Direct Submission
20	JN633888	*Elephas maximus*	EEHV 1A	USA	J. Zoo Wildl. Med. 44 (1), 42-54 (2013)
21	MF579066	*Elephas maximus*	EEHV 1A	India	J. Wildl. Dis. 49 (2), 381-393 (2013)
22	KT852705	*Elephas maximus*	EEHV 1A	Thailand	Direct Submission
23	KR812388	*Elephas maximus*	EEHV 1A	Thailand	Direct Submission
24	KT832533	*Elephas maximus*	EEHV 1A	India	Direct Submission
25	KT705214	*Elephas maximus*	EEHV 1A	United Kingdom	Direct Submission
26	MF579069	*Elephas maximus*	EEHV 1A	India	J. Wildl. Dis. 49 (2), 381-393 (2013)
27	KY888884	*Elephas maximus*	EEHV 1A	USA	Direct Submission
28	KC462164	*Elephas maximus*	EEHV 1A	United Kingdom	Direct Submission
29	JX011037	*Elephas maximus*	EEHV 1A	India	Direct Submission
30	MG821350	*Elephas maximus*	EEHV 1A	Malaysia	Direct Submission
31	MG821348	*Elephas maximus*	EEHV 1A	Malaysia	Direct Submission
32	ON129566	*Elephas maximus*	EEHV 1A	India	Direct Submission
33	XM001616212	---	Plasmodium Vivax	---	Direct Submission

Discussion

India is one of the landscapes that harboured Asian elephants from time immemorial. The species is now endangered due to a lack of habitat, poaching for tusks and human-animal conflict. Though the country has a significant population of Asian elephants, only a few reports of EEHV have surfaced from the region. The population of elephants in India was 53,000 in 2012. There are two important populations of elephants in the country, first the north-eastern frontier and the southern Deccan plateau population. The population of central India is limited to states of Madhya Pradesh, Chhattisgarh and Maharashtra. Though the population of wild elephants in the central Indian landscape is not significant, but the landscape is very important considering the migration and gene flow of the elephants. Till date, not more than five reports have emerged from India from 2000 [9, 12, 13, 14, 15]. The EEHV threatens the species as young calves suffer significant mortality due to the infection. The majority of the cases that have been reported from around the world are from domesticated and captive elephants. Very little information from free-ranging herds is available due to limited opportunities to sample from the wild stock. Though the case report is an isolated incidence of EEHV in an elephant calf from India, very little information on EEHV has been reported from the country. The central Indian landscape connects the eastern and the southern landscapes. Currently, very few herds of wild elephants are present in the landscape. There has been a history of EEHV in the herd in which the death was reported. The age, post-mortem lesions and clinical signs were suggestive of EEHV; hence, a detailed histopathological and molecular investigation was carried out. Blood samples were collected from all the animals in the herd and screened for EEHV.

A detailed study of histopathology, molecular methods & phylogenetic analysis was undertaken to generate epidemiologically significant data. It has been reported that elephant calves that are recently weaned are more prone to EEHV [16]. EEHV IA was previously reported in the country in 2013 (South India) [9] and 2017 (Assam) [13], and the current case report provides further evidence of the circulating EEHV in India. The EEHV has an acute onset in young calves, and most of the gross post-mortem changes indicate haemorrhagic changes in the visceral organs. The changes are attributed to virus-induced increases in the permeability of blood vessels alone or in conjunction with the endothelial cell lysis [17]. The same was noticed in the case and was confirmed with histopathological studies. The PCR was performed to understand the tissue distribution of the virus in the visceral organs. The virus had even distribution in all the organs of the elephant except the lymph nodes. The tongue and heart had a good concentration of the virus and can be utilised as a tissue of preference for the detection of EEHV from post-mortem samples.

There are many EEHV serotypes that are reported in Asian elephants. An effort was made to screen all the serotypes of EEHV to accurately detect the circulating strain and rule out the possibility of a co-infection [18]. In the current study, the primers targeting EEHV 1, 2, 3, 4, 5, 6 & 7 were used, followed by identification based on sequencing. The reported sequence was similar to the reported sequence of EEHV 1A reported from Assam, India (Accession No. OP222134) and Switzerland (Accession No. JF692769). The sequence alignment and phylogenetic analysis were performed using the Mega X software, the KT832533 which is a previously reported sequence of EEHV from Tadoba-Andhari Tiger Reserve (Maharashtra, India) in 2013 was preferentially included. The sequence was aligned with the sequence to understand the changes in the two sequences at the U38 protein of the DNA polymerase gene. The amino acid alignment revealed four substitutions in the U38 protein; out of the 135 amino acid sequences compared, the following substitutions were noted S28W, L47F, D124N and R127I (Fig. 9). The sequence KT832533 has been reported from the same landscape of Maharashtra State of India, as the case under consideration; however, the sequences appear to be distinct from each other and share 98.91% identity and are placed in the Clade I of the phylogenetic tree. Hence the sequence formed a separate clade at the bottom of the tree.

Summing up, Asiatic elephants have a cultural and aesthetic value in India; their ecological value in the ecosystem is colossal. EEHV is a significant disease of the Asiatic elephants; very little data on the status of the disease in the free range is available. Considering the dynamic nature of the virus, herding nature of the species, impact on juvenile calves and lifelong shedding of the virus from adult carriers, it is required to profoundly investigate the prevalence and impact of the disease in free range and captive elephants.

Conclusion

In conclusion, the comprehensive histopathological, molecular, and phylogenetic analyses conducted in response to a case of Elephant Endotheliotropic Herpesvirus (EEHV) infection in an Asian elephant calf provide valuable insights into the epidemiology and pathology of this significant disease. The observed histopathological changes, coupled with positive PCR results and molecular sequencing, confirmed the presence of EEHV IA, with a sequence closely resembling strains previously reported in both India and Switzerland. Furthermore, phylogenetic analysis highlighted distinct clades of EEHV IA strains, underscoring the need for continued surveillance and research on this virus's genetic diversity and distribution. This case underscores the vulnerability of Asian elephants to EEHV and emphasizes the importance of comprehensive monitoring and management strategies to safeguard both wild and captive populations of this culturally and ecologically significant species in India.

Abbreviations

EEHV: Elephant Endotheliotropic Herpes Virus
PCR: Polymerase Chain Reaction
NCBI: National Center for Biotechnology Information
DNA: Deoxyribonucleic Acid
bp: base pairs

Declarations

Ethics approval and consent to participate: No experiments were performed on the wild animals in the reported study. The samples were collected for clinical and diagnostic purpose. Hence does not draw the ethical committee approval as per the rules in India. Samples from the post mortem examination of tiger cub under reference No. 21 of Table 1 has been collected as per the request letter no Desk-3/ Vigilance/DD/ PTR/390/ 22-23, Nagpur dated 06/05/2022. As per the existing Wildlife Protection Act,

1972 permission from Principal Chief Conservator of Forest (Wildlife), Maharashtra State was sought to vide No. Desk-22(8)/Res/CR-59(19-20)/3838/19-20, Nagpur, date 15 January 2020; vide No. Desk-22(8)/Res/CR-59(19-20)/2370/20-21, Nagpur, date 07 January 2021 and vide No. Desk-22(8)/Res/CR-59(19-20)/2565/2021-22, Nagpur, date 18 January 2022 for the study and publication of scientific findings.

Reporting Animal Experiments: No experiments have been carried out on animals and the samples were collected for the diagnosis wherein required permissions from the PCCF (Wildlife) of Maharashtra State (India) as per the provisions of the Wildlife Protection Act, 1972 have been obtained. For the herd screening from live animals, the sample collection has been undertaken as per the ARRIVE guidelines.

Consent for publication: Not Applicable.

Availability of Data & Materials: The sequence identified in the study is available in the public domain database of NCBI under Accession No. ON129566
https://www.ncbi.nlm.nih.gov/nuccore/on129566

Competing interests: The authors declare that they have no competing interests.

Funding: The authors self-funded the study. The Corresponding author is not in receipt of any funding from research agencies in India or abroad.

Authors' Contributions
KSM major contributor and involved in all phases of research, including writing the manuscript, performing PCR and sequencing., KMP, PMD, DVM, BBK & GAP performed the post mortem examination, collected samples and performed the histopathology investigation. USV& KRM performed phylogenetic analysis and assisted in manuscript preparation. All authors have read and approved the final manuscript.

Acknowledgment
The authors acknowledge the kind approval of the Principal Chief Conservator of Forest (Wildlife) & Chief Wildlife Warden, Maharashtra State, for carrying out the research work. Forest Development Corporation of Maharashtra Ltd., Nagpur and Office of the Divisional Manager, Gorewada Project, Nagpur, for the facilities provided for the research. Deputy Conservator of Forest, Sironcha & Director, Wildlife Research & Training Centre to facilitate the research work at WRTC, Gorewada, Nagpur.

References
1. Hayward GS. Conservation: clarifying the risk from herpesvirus to captive Asian elephants. Vet Rec. 2012;170(8):202.
2. Fickel J, Richman LK, Montali R, Schaftenaar W, Göritz F, Hildebrandt TB, Pitra C. A variant of the endotheliotropic herpesvirus in Asian elephants (*Elephas maximus*) in European zoos. Vet Microbiol. 2001;82(2):103-109.
3. Latimer E, Zong JC, Heaggans SY, Richman LK, Hayward GS. Detection and evaluation of novel herpesviruses in routine and pathological samples from Asian and African elephants: identification of two new probosciviruses (EEHV5 and EEHV6) and two new gammaherpesviruses (EGHV3B and EGHV5). Vet Microbiol. 2011;147(1-2):28-41.
4. Yun Y, Sripiboon S, Pringproa K, Chuammitri P, Punyapornwithaya V, Boonprasert K, *et al*. Clinical characteristics of Elephant Endotheliotropic Herpesvirus (EEHV) cases in Asian elephants (*Elephas maximus*) in Thailand during 2006–2019. Vet Q. 2021;41(1):268-279.
5. Boonprasert K, Punyapornwithaya V, Tankaew P, Angkawanish T, Sriphiboon S, Titharam C, *et al*. Survival analysis of confirmed elephant endotheliotropic herpes virus cases in Thailand from 2006–2018. PLoS One. 2019;14(7):e0219288.
6. Prompiram P, Wiriyarat W, Bhusri B, Paungpin W, Jairak W, Sripiboon S, *et al*. The occurrence of Elephant Endotheliotropic Herpesvirus infection in wild and captive Asian elephants in Thailand: Investigation based on viral DNA and host antibody. Vet World. 2021;14(2):545.
7. Fuery A, Pursell T, Tan J, Peng R, Burbelo PD, Hayward GS, Ling PD. Lethal hemorrhagic disease and clinical illness associated with elephant endotheliotropic herpesvirus 1 are caused by primary infection: Implications for the detection of diagnostic proteins. J Virol. 2020;94(3):e01528-19.
8. Hoornweg TE, Schaftenaar W, Maurer G, van den Doel PB, Molenaar FM, Chamouard-Galante A, *et al*. Elephant endotheliotropic herpesvirus is omnipresent in elephants in European zoos and an Asian elephant range country. Viruses. 2021;13(2):283.
9. Zachariah A, Zong JC, Long SY, Latimer EM, Heaggans SY, Richman LK, *et al*. Fatal herpesvirus hemorrhagic disease in wild and orphan Asian elephants in southern India. J Wildl Dis. 2013;49(2):381-393.
10. Bhusri B, Suksai P, Mongkolphan C, Tiyanun E, Ratanakorn P, Chaichoun K, *et al*. Detection of elephant endotheliotropic herpesvirus 4 in captive Asian elephants (*Elephas maximus*) in Thailand. Thai J Vet Med. 2017;47(1):97-102.
11. Kumar S, Stecher G, Li M, Knyaz C, Tamura K. MEGA X: molecular evolutionary genetics analysis across computing platforms. Mol Biol Evol. 2018;35(6):1547.
12. Stanton JJ, Nofs SA, Zachariah A, Kalaivannan N, Ling PD. Detection of Elephant Endotheliotropic Herpesvirus infection among healthy Asian elephants (*Elephas maximus*) in South India. J Wildl Dis. 2014;50(2):279-87.
13. Mahato G, Sarma KK, Pathak DC, Barman NN, Gogoi P, Dutta M, *et al*. Endotheliotropic herpesvirus infection in Asian elephants (*Elephas maximus*) of Assam, India. Vet World. 2019;12(11):1790.
14. Barman NN, Choudhury B, Kumar V, Koul M, Gogoi SM, Khatoon E, *et al*. Incidence of Elephant Endotheliotropic Herpesvirus in Asian elephants in India. Vet Microbiol. 2017;208:159-63.
15. Lakshmi PS, Karikalan M, Sharma GK, Sharma K, Mohan SC, Kumar KR, *et al*. Pathological and molecular studies on elephant endotheliotropic herpesvirus haemorrhagic disease among captive and

free-range Asian elephants in India. Microb Pathog. 2023;175:105972.
16. Perrin KL, Nielsen SS, Martinussen T, Bertelsen MF. Quantification and risk factor analysis of elephant endotheliotropic herpesvirus-haemorrhagic disease fatalities in Asian elephants (*Elephas maximus*) in Europe (1985-2017). J Zoo Aquar Res. 2021 Jan 31;9(1):8-13.
17. Thachil J. Disseminated intravascular coagulation–new pathophysiological concepts and impact on management. Expert Rev Hematol. 2016;9(8):803-814.
18. Zong JC, Heaggans SY, Long SY, Latimer EM, Nofs SA, Bronson E, *et al*. Detection of quiescent infections with multiple elephant endotheliotropic herpesviruses (EEHVs), including EEHV2, EEHV3, EEHV6, and EEHV7, within lymphoid lung nodules or lung and spleen tissue samples from five asymptomatic adult African elephants. J Virol. 2016;90(6):3028-3043.